

From the Department of Oral and Plastic Maxillofacial Surgery

Director: Prof. Dr. med. habil. Dr. med. dent. B. Frerich

**Prospective clinical study comparing intraligamentary  
anesthesia and inferior alveolar nerve block for extraction  
of mandibular posterior teeth**

Inaugural Dissertation

to

Obtain the academic degree

Doctor of Dentistry

Faculty of Medicine

University of Rostock

Submitted by

Ahmed Adubae / Born 09/03/1978

from Taiz/Yemen

Rostock 2016

Dean: Prof. Dr. med. univ. Emil Christian Reisinger

Reviewer:

1. PD Dr. med. habil. Dr. med. Dent. Peer- Wolfgang Kämmerer, MA, Department of Oral and Plastic Maxillofacial Surgery, University of Rostock
2. Prof. Dr. med. Dr. med. dent. Dr. med. h. c. Karsten Gundlach, Former director of the Department of Oral and Plastic Maxillofacial Surgery, University of Rostock
3. Univ.-Prof. Dr. med. habil. Dr. med. dent. Monika Daubländer, Department of Oral and Plastic Maxillofacial Surgery - University of Mainz

Date of submission: 26/September/2016

Date of defense: 21/March/2017

For the soul of my parents  
and for my family...

**Table of Contents**

	<b>Page</b>
• List of tables	VI
• List of figures	VII
• Abbreviations	VII
<b>1 Introduction</b>	<b>1</b>
<b>2 Review of the literature</b>	<b>3</b>
2.1 Pain control in dentistry	3
2.1.1 Local anesthesia in dentistry	3
2.1.1.1 Superficial anesthesia	4
2.1.1.2 Infiltration anesthesia	5
2.1.1.3 Conduction anesthesia	5
2.1.1.4 Intraligamentary anesthesia	6
2.2 Inferior alveolar nerve block (IANB)	6
2.2.1 Techniques of IANB	7
2.2.1.1 Conventional direct technique	7
2.2.2 Anesthetic profile of IANB	8
2.2.3 Indications and contraindications of IANB	9
2.2.4 Advantages of IANB	9
2.2.5 Disadvantages of IANB	9
2.2.6 Complications of IANB	10
2.2.6.1 Failure of the anesthesia	10
2.2.6.2 Nerve injury	11
2.2.6.3 Injury to blood vessels and inadvertent intravascular injection	11
2.2.6.4 Muscle injury and trismus	12
2.2.6.5 Needle breakage	12
2.2.6.6 Self-inflicted soft tissue injury	12
2.2.6.7 Transient facial nerve paralysis	12
2.3 Intraligamentary anesthesia (ILA)	13
2.3.1 Instruments for ILA	13
2.3.1.1 Mechanical injection systems	13
2.3.1.1.1 Pistol type syringes	13
2.3.1.1.2 Penholder grip syringes	14
2.3.1.1.3 Dosing wheel systems	15
2.3.1.2 Electronically controlled injection systems	15
2.3.1.3 Needles	16
2.3.2 Technique of ILA	16

2.3.3	Mechanism of action of ILA	18
2.3.3.1	Vascular distribution	18
2.3.3.2	Medullary distribution	18
2.3.3.3	Combination of vascular and medullary distributions	19
2.3.4	Limitations of ILA	19
2.3.5	Anesthetic profile of ILA	20
2.3.6	Indications of ILA	20
2.3.7	Contraindications of ILA	21
2.3.8	Complications of ILA	22
2.3.8.1	Damage to periodontal tissues	22
2.3.8.2	Bone and root resorption	23
2.3.8.3	Soft tissue necrosis	23
2.3.8.4	Impaired wound healing (dry socket)	23
2.3.8.5	Bacteremia	24
2.3.8.6	Unwanted side effects	24
2.3.8.7	Hypoplasia of permanent teeth	25
<b>3</b>	<b>Aims of the study</b>	25
3.1	Problem and objectives	25
<b>4</b>	<b>Materials and methods</b>	27
4.1	Design of the study	27
4.2	Materials	27
4.2.1	Patients	27
4.2.1.1	Inclusion criteria	27
4.2.1.2	Exclusion criteria	28
4.2.2	Materials for IANB	28
4.2.3	Material for ILA	28
4.2.4	Data collection	28
4.3	Methods	29
4.3.1	Method of administering IANB	29
4.3.2	Method of administering ILA	30
4.3.3	Documentation of anesthetic effect	30
4.3.4	Statistical methods	32
<b>5</b>	<b>Results</b>	33
5.1	Evaluation group I	33
5.1.1	Patients and teeth	33

5.1.2	General parameters	35
5.1.2.1	Age, height and body weight	35
5.1.3	Parameters of the primary objectives of this study	35
5.1.3.1	Pain of injection	35
5.1.3.2	Pain during tooth extraction	36
5.1.3.3	Unpleasantness of treatment	36
5.1.3.4	Quality of the anesthetic effect as assessed by patients	37
5.1.3.5	Need for second injection	39
5.1.4	Parameters of the secondary objectives of this study	40
5.1.4.1	Amount of local anesthetic solution used at the initial injection	40
5.1.4.2	Latency of anesthesia	40
5.1.4.3	Time between injection and start of extraction procedure	41
5.1.4.4	Time until second injection and amount of anesthetic solution at second injection	42
5.1.4.5	Duration of entire treatment	42
5.1.4.6	Quality of the anesthetic effect as assessed by the dentist	43
5.1.4.7	Duration of soft tissue anesthesia	44
5.1.4.8	Frequency of associated complications	45
5.2	Evaluation group II (patients with split-mouth technique)	45
5.2.1	Patients and teeth	45
5.2.2	Parameters of the primary objectives of this study	47
5.2.2.1	Pain of injection	47
5.2.2.2	Pain during tooth extraction	47
5.2.2.3	Unpleasantness of treatment	47
5.2.2.4	Quality of the anesthetic effect as assessed by patients	48
5.2.2.5	Need for second injection	49
5.2.3	Parameters of the secondary objectives of this study	50
5.2.3.1	Amount of local anesthetic solution used at initial injection and latency time of anesthesia	50
5.2.3.2	Time between injection and start of extraction procedure	51
5.2.3.3	Duration of entire treatment	51
5.2.3.4	Quality of the anesthetic effect assessed by the dentist	51
5.2.3.5	Duration of soft tissue anesthesia	52
5.2.3.6	Frequency of associated complications	53
<b>6</b>	<b>Discussion</b>	<b>54</b>
<b>7</b>	<b>Conclusion</b>	<b>64</b>
<b>8</b>	<b>Summary</b>	<b>66</b>

<b>9</b>	<b>References</b>	<b>69</b>
<b>10</b>	<b>Declaration of original work</b>	<b>78</b>
<b>11</b>	<b>Theses</b>	<b>79</b>
<b>12</b>	<b>Curriculum Vitae</b>	<b>80</b>
<b>13</b>	<b>Acknowledgements</b>	<b>82</b>
<b>14</b>	<b>Appendix</b>	<b>83</b>

**List of tables**

<b>Table 1:</b>	Frequency of teeth extractions in group I	34
<b>Table 2:</b>	Mean height and body weight related to anesthetic technique	35
<b>Table 3:</b>	Pain of injection related to anesthetic technique	36
<b>Table 4:</b>	Pain during tooth extraction related to anesthetic technique	36
<b>Table 5:</b>	Unpleasantness of treatment related to anesthetic technique	37
<b>Table 6a:</b>	Quality of anesthetic effect assessed by patients	38
<b>Table 6b:</b>	Complete/sufficient versus insufficient/no anesthetic effect assessed by patients	38
<b>Table 6c:</b>	Complete versus sufficient anesthetic effect assessed by patients	39
<b>Table 7:</b>	Frequency of second injections necessary related to anesthetic technique	39
<b>Table 8:</b>	Amount of the initially used local anesthetic solution related to anesthetic technique	40
<b>Table 9:</b>	Latency time of anesthesia related to anesthetic technique	40
<b>Table 10:</b>	Time between injection and start of extraction procedure	41
<b>Table 11:</b>	Time until second injection and amount of local anesthetic for the second injections related to anesthetic technique	42
<b>Table 12:</b>	Duration of treatment related to anesthetic technique	43
<b>Table 13a:</b>	Quality of anesthetic effect assessed by the dentist	43
<b>Table 13b:</b>	Complete/sufficient effect versus insufficient/no anesthetic effect assessed by the dentist	44
<b>Table 13c:</b>	Complete versus sufficient anesthetic effect assessed by the dentist	44
<b>Table 14:</b>	Duration of soft tissue anesthesia related to anesthetic technique	44
<b>Table 15:</b>	Frequency of teeth extractions in group II	46
<b>Table 16:</b>	Pain of the injection related to anesthetic technique	47
<b>Table 17:</b>	Pain during tooth extraction related to anesthetic technique	47
<b>Table 18:</b>	Unpleasantness of treatment related to anesthetic technique	48
<b>Table 19a:</b>	Quality of anesthetic effect assessed by patients	49
<b>Table 19b:</b>	Complete/sufficient effect versus insufficient/no effect assessed by patients	49
<b>Table 20:</b>	Frequency of second injections necessary related to anesthetic technique	50
<b>Table 21:</b>	Amount of initially used local anesthetic solution and the latency time of anesthesia	50
<b>Table 22:</b>	Time between injection and start of extraction procedure	51
<b>Table 23:</b>	Duration of treatment related to anesthetic technique	51
<b>Table 24a:</b>	Quality of anesthetic effect assessed by the dentist	52
<b>Table 24b:</b>	Complete/sufficient effect versus insufficient effect assessed by the dentist	52
<b>Table 25:</b>	Duration of soft tissue anesthesia related anesthetic technique	52
<b>Table 26:</b>	Frequency of occurrence of impaired wound healing (dry socket)	53



**List of figures**

<b>Figure 1:</b>	Conventional direct technique for IANB	8
<b>Figure 2:</b>	Ultraject® syringe (Sanofi-Aventis)	14
<b>Figure 3:</b>	Intraligamentary injection	17
<b>Figure 4:</b>	Mechanism of action of ILA	19
<b>Figure 5:</b>	Bar charts showing number of extracted teeth per anesthetic technique	34
<b>Figure 6:</b>	Box plots showing differences in pain of injection, pain during tooth extraction, and unpleasantness of treatment	37
<b>Figure 7:</b>	Box plots showing time from injection of local anesthetic to onset of full anesthetic effect and time from injection to start of tooth extraction	41
<b>Figure 8:</b>	Box plots comparing duration of soft tissue anesthesia in cases of ILA and IANB	45
<b>Figure 9:</b>	Bar charts showing number of extracted teeth per anesthetic technique in group II	46
<b>Figure 10:</b>	Box plots showing differences in pain of injection, pain during tooth extraction, and unpleasantness of treatment in group II	48

**Abbreviations**

<b>C-CLAD</b>	Computer controlled local anesthetic delivery system
<b>DPS</b>	Dynamic pressure sensor
<b>IANB</b>	Inferior alveolar nerve block
<b>ILA</b>	Intraligamentary anesthesia
<b>LED</b>	Light-emitting diode
<b>MPa</b>	MegaPascal
<b>N</b>	Newton
<b>NSAD</b>	Non-steroid anti-inflammatory drugs
<b>NRS</b>	Numeric rating scale
<b>SD</b>	Standard Deviation
<b>STA</b>	Single tooth anesthesia

## **1. Introduction**

The control of pain and discomfort has always been an important part of medicine and dentistry and is an essential part of the successful practice in dentistry today. Providing an efficient local anesthesia is of utmost importance in gaining patient's trust and cooperation in dentistry and to complete treatment successfully. Tooth extraction is one of the most common dental procedures requiring local anesthesia. In the upper jaw, teeth are usually extracted under local infiltration anesthesia as the bony anatomy of the upper jaw enables the diffusion of the local anesthetic solution in sufficient amounts into its working site. In adults, the bone anatomy in the posterior part of the mandible allows, however, no adequate diffusion of the anesthetic solution. In accordance, other anesthetic techniques are required for extraction of mandibular posterior teeth. Until today, the inferior alveolar nerve block is the most commonly used technique for providing local anesthesia in the posterior mandible [Foster et al., 2007]. However, this technique is painful and has a relatively high failure rate and technique immanent risks, such as transient or even persistent damage of the lingual and/or the inferior alveolar nerve. Consequently, there is an increasing demand for alternative local anesthetic techniques with higher success rate and minimal risk of complications [Shabazfar et al., 2014].

Considering the legal demand of informing the patient about possible risks of an indicated health measure and about available alternatives [Bluttner and Taubenheim, 2009], the question arises whether intraligamentary anesthesia as a primary anesthetic technique can meet the requirement of a relatively complete and patient-friendly local anesthetic technique and whether it can be considered as a valid alternative to the conventional inferior alveolar nerve block for simple extraction of mandibular posterior teeth.

So far, there are only few comparative studies of low evidence comparing intraligamentary and inferior alveolar nerve block anesthesia in the extraction of mandibular posterior teeth [Heizmann, 1987; Dumbrigue et al., 1997]. These studies showed that intraligamentary anesthesia is at least not inferior to nerve block anesthesia for this indication. Each of these two studies used a different injection system for the administration of intraligamentary anesthesia.

The objective of the present study was to test the technique of intraligamentary anesthesia – here using a pistol type syringe with pressure limitation (Ultraject®). The question was whether this can be considered as a valid alternative to the inferior

alveolar nerve block for extraction of mandibular posterior teeth. The primary objectives were to evaluate the difference in pain perceived by the patients during treatment as well as the anesthetic efficacy (complete/sufficient vs. insufficient/no effect) based on the outcome of treatment and the degree of discomfort associated with the extraction procedure. The pain of injection, need for second injection, amount of anesthetic solution, and duration of the local numbness were also assessed. A further objective of the study was to clarify whether impaired wound healing (dry socket) was more frequent after intraligamentary anesthesia, as alluded by some authors [Brännström et al., 1982; Meechan et al., 1987].

It was hypothesized that intraligamentary anesthesia applied using a pistol-type syringe with a built-in pressure limiting mechanism enables a patient-friendly, pain- and complication-less extraction of teeth in the posterior mandible. If so, intraligamentary anesthesia could be a standard technique for this indication.

## **2. Review of the literature**

### **2.1. Pain control in dentistry**

Dentistry and pain are synonymous for many patients. Therefore, many patients avoid routine dental treatment [Thomason et al., 1999]. The patient's perception of dental treatment is closely related to the anesthetic experience he has had [Kohler et al., 2008]. So, proper management of pain and attainment of adequate analgesia in the operating field are of pivotal importance in dentistry.

In consideration of the patient's general condition, nature and extent of the planned therapy as well as the available facilities in the dental clinic, all of the possible pain control methods should be considered and discussed with the patient. For effective pain control one or more of the following methods should be kept in mind:

- Administration of local anesthesia.
- Psychological management of the patient and establishment of a good doctor-patient relationship.
- Medical sedation, especially in case of anxious patients.
- Administration of general anesthesia for special indications.
- Suggestion and possibly hypnosis.

Apart of the few indications for general anesthesia in dentistry such as in invasive dentoalveolar surgical procedures and in treating non-cooperative patients, the elimination of pain in dentistry has so far been conducted largely by conventional methods of local anesthesia such as nerve block and/or infiltration anesthesia [Csides, 2009].

#### **2.1.1. Local anesthesia in dentistry**

Local anesthesia is considered as the backbone of pain control in dentistry and is the most widely practiced method of pain control in dentistry today. In the last decades, however, great advances in the types of anesthetic agents, delivery devices, and techniques have been achieved [Saxena et al., 2013]. With these advances, it became possible to render surgical and extensive conservative dental treatment measures bearable for the patients with minimal side effects and complications. In dentistry, local anesthesia is mostly obtained through:

- Application of a local anesthetic agent on the mucous membrane or skin (superficial anesthesia).
- Injection of a local anesthetic solution directly into the surgical site (infiltration anesthesia, terminal anesthesia).
- Injection of a local anesthetic solution at the nerve trunk (conduction, nerve block anesthesia).
- Injection of a local anesthetic solution into the periodontal ligament space of the tooth to be treated (intraligamentary anesthesia, periodontal ligament injection).
- Intraosseous injection of a local anesthetic solution using special injection systems (intraosseous anesthesia).
- Injection of a local anesthetic solution into the inter-dental septum (intra-septal anesthesia).
- Injection of a local anesthetic solution directly into the dental pulp (intra-pulpal anesthesia).

Local anesthesia is considered as a safe method of pain control. Yet regardless of how beneficial a health care procedure may be, there are always associated disadvantages and risk of complications. Therefore, the patients should always be informed about possible complications of the local anesthesia such as soft tissue injury, necrosis in the injection area, nerve injury, prolonged bleeding, excessive hematoma, needle breakage, and possible allergic reactions.

#### **2.1.1.1. Superficial anesthesia**

For superficial anesthesia, the local anesthetic, in a form of spray or gel, is applied to the mucosa. It reaches the superficial nerve endings by local diffusion. The anesthetic effect is limited to the mucosa and usually not sufficient to eliminate the pain of dental treatment. It rather reduces the piercing pain of a subsequent injection. However, superficial anesthesia is not always enough to complete elimination of this pain of injection [Mayer, 1976; Kaufman et al., 2005]. By combining superficial anesthesia with infiltration or conduction anesthesia, it is to be noticed that the amount of the applied surface anesthetic must be added to the total maximum administrable dose. Especially in children, this can easily result in exceeding the limit of maximal dose and cause intoxication [Krüger, 1993].

#### **2.1.1.2. Infiltration anesthesia**

For infiltration anesthesia, usually 0.5-1.5 ml of the local anesthetic solution is injected in the immediate vicinity of the bone surface (submucosal or suprapariosteal) most often only in the upper jaw or in the anterior part of the lower jaw. The injected solution diffuses in the soft tissue and through the adjacent bone and reaches the terminal nerve endings of the teeth. The anesthetic effect usually begins within 1-3 minutes after the injection and includes the region of the respective tooth, the gingiva, and the vestibular soft tissues [Rahn, 2003]. Due to its success rate of up to 95% and its technically simple application, infiltration is the most commonly used local anesthetic technique [Kämmerer et al., 2010]. In the posterior part of the adult mandible, the local anesthetic solution cannot sufficiently diffuse through the thick compact layer of bone, and hence, infiltration anesthesia is not adequate in this region.

#### **2.1.1.3. Conduction anesthesia**

For conduction anesthesia, the local anesthetic solution is injected in the immediate vicinity of the nerve trunk, usually at its bony exit or entry point (foramen). This results in anesthesia of the entire area innervated by this nerve distal to the injection site. Using only a single injection and a relatively small amount of local anesthetic solution, a complete anesthesia of sufficiently long duration in a wide operation field can usually be obtained with this technique [Malamed, 1997]. However, the duration of anesthesia after a successful nerve block is significantly longer than that required for most dental procedures, so that the patient remains limited in his disposition ability often for hours after completion of treatment [Dirnbacher, 2003; Weber et al., 2005; Prothmann et al., 2010]. Articulation and mastication are affected and the risk of postoperative bite and burn injuries is increased [Chi et al., 2008]. Since the local anesthetic has to be injected in the immediate vicinity of the nerve and because the nerve itself cannot be exactly located during the injection, this technique of local anesthesia is associated, on one hand, with a higher failure rate, and on the other hand, with an increased risk of nerve injury. Nerve block anesthesia is primarily indicated when no or only insufficient depth of anesthesia can be achieved with infiltration anesthesia such as in the posterior part of the mandible and for extended dental and dentoalveolar surgical procedures.

More than 16 million nerve block anesthetics were administered in Germany in 2013 [Bender and Taubenheim, 2014]. Commonly used nerve block anesthesia in dentistry includes inferior alveolar, mental, and buccal nerve blocks in the lower jaw; and superior posterior alveolar, superior anterior alveolar, nasopalatal, and greater palatal nerve blocks in the upper jaw.

#### **2.1.1.4. Intraligamentary anesthesia**

The technique of intraligamentary anesthesia, i.e. the injection of the anesthetic solution into the periodontal ligament space, was first described in the medical literature about 100 years ago. At the beginning of the 20<sup>th</sup> century, in France, attempts were made to inject the local anesthetic solution into the periodontal ligament space to anesthetize the teeth to be extracted. The first intraligamentary anesthesia was applied by Granjeon in 1903; this was described by Chompret and first publicized by Bourdin in his doctoral thesis in 1925 [Bourdin, 1925].

Although intraligamentary anesthesia, already at that time, was considered to be an interesting method of local anesthesia, it did not become established because of the inadequacy of the injection instruments available at that time. The medico-technical advances in the last few years have opened new possibilities for this method of local anesthesia and enabled the dentist to apply it as a minimally invasive technique for a variety of indications.

In the technique of intraligamentary anesthesia, the local anesthetic solution is injected under controlled high pressure by means of special injection systems into the periodontal ligament space of the tooth to be anesthetized. This results in a profound anesthesia with an immediate onset of action and an anesthetic duration of approximately 30-45 minutes using only a small amount of local anesthetic solution (0.2 ml for each root); thereby, reducing the risk of systemic intoxication [Daubländer and Kämmerer, 2014]. The anesthesia is limited to a single tooth and its supporting structures while anesthesia of the lips, cheeks, and tongue is avoided.

#### **2.2. Inferior alveolar nerve block (IANB)**

IANB is the most frequently used form of conduction anesthesia when performing restorative or surgical procedures in the posterior mandible. The local anesthetic solution is injected in the proximity of the inferior alveolar nerve in the

pterygomandibular space just before it enters the mandibular canal at the mandibular foramen. It provides anesthesia of the ipsilateral mandibular teeth from the third molar almost up to the midline and allows carrying out most dentoalveolar procedures in the mandible.

### **2.2.1. Techniques of IANB**

The IANB can be approached from intra- and extra-orally; in general the intraoral approaches are most commonly used [Lipp, 1992]. Intra-orally, three techniques have been proven to be effective (the conventional, the Gow-Gates, and the Vazirani-Akinosi technique). In the present study only the conventional direct technique of IANB was used because it has established itself as the dominant technique in daily practice. Therefore, the discussion of the technique in the following paragraphs refers only to the conventional direct technique of IANB.

#### **2.2.1.1. Conventional direct technique**

The conventional direct technique involves the insertion of the needle into the pterygomandibular space by piercing the buccinator muscle and the deposition of the local anesthetic solution at a level just superior to the mandibular foramen [Khoury et al., 2011]. For the correct application, the height of the injection, the placement of the needle, and the depth of penetration must be considered. The posterior ramus is grasped, with the thumb placed intra-orally in the coronoid notch retracting the soft tissue laterally. An imaginary line extends posteriorly from the fingertip in the coronoid notch to the pterygomandibular raphe (as it turns up towards the maxilla) and determines the height of injection. This imaginary line should be parallel to the occlusal plane of the mandibular molars. In the majority of patients, this line will be 6-10 mm above the occlusal plane. A long dental needle is directed from the corner of the mouth of the contralateral side with the barrel of the syringe lying above the mandibular premolars. The needle is inserted lateral to the pterygomandibular raphe and advanced gently within the pterygomandibular space until bone is contacted at a 2-2.5 cm penetration depth (Figure 1). If bone is contacted too soon, the needle tip is located too far laterally on the ramus; in case of no bone contact, the needle tip is usually located too far medially [Malamed, 1997].



Once the bone is contacted, the needle is withdrawn slightly to avoid subperiosteal injection, aspiration is done in two planes and – if negative – an average of 1.5 ml of anesthetic solution is injected slowly [Reed et al., 2012; Prama et al., 2013]. Afterwards, the needle is withdrawn for approximately 1 cm and the barrel of the syringe is moved slightly toward the dental midline and a further 0.3-0.5 ml of local anesthetic solution is injected to anesthetize the lingual nerve.

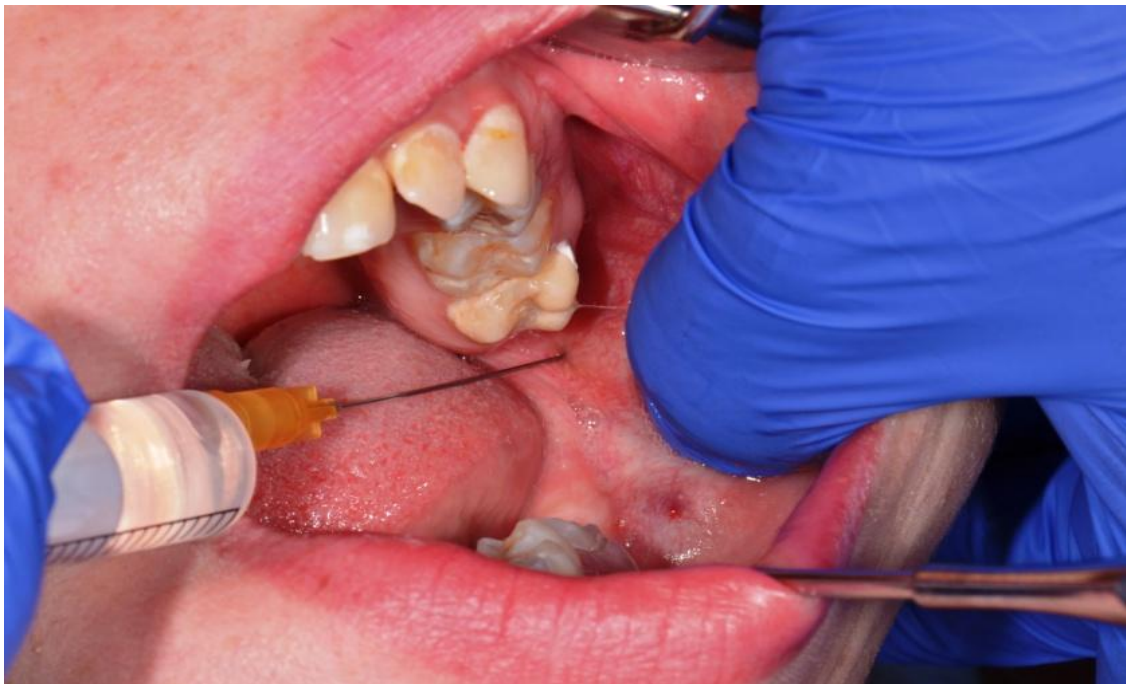

Figure 1: Conventional direct technique for IANB

### **2.2.2. Anesthetic profile of IANB**

IANB provides anesthesia of the ipsilateral mandibular teeth from the third molar almost up to the midline, the buccal soft tissue from the premolars anteriorly, the body of the mandible, the periosteum, the periodontal ligaments, and the skin and subcutaneous tissues of the chin and lower lip, all on the ipsilateral side [Reed et al., 2012]. The lingual nerve and sometimes also the buccal nerve are frequently anesthetized by the same injection technique resulting in the extension of the anesthetized area to include the lingual gingiva, floor of the mouth, side of the tongue and the buccal gingiva and soft tissues from third molar to the second premolar area of the same side.

The average latency time of the anesthesia is reported to be significantly more than 3 minutes and the duration of the soft tissue anesthesia is usually 2-4 hours [Shabazfar et al., 2014], which is frequently significantly longer than the time required to carry out most of the dental treatments. The simultaneous numbness of the tongue and the lower lip is often unpleasant for many patients and the risk of a bite or burn injury of the still anesthetized soft tissues increases [Chi et al., 2008].

### **2.2.3. Indications and contraindications of IANB**

IANB is indicated primarily for invasive conservative, prosthetic, and surgical treatment of multiple mandibular posterior teeth. Due to the risk of injury to the blood vessels and hematoma formation, IANB is relatively contraindicated in patients with bleeding diathesis or those with anticoagulant therapy. In these patients it is advised to use another technique of local anesthesia [Stoll and Bührmann, 1983; Stoll et al., 1986; Heizmann and Gabka, 1994].

### **2.2.4. Advantages of IANB**

- Profound anesthesia in a relatively wide area is obtained with only one injection (useful for quadrant dentistry) [Malamed, 1997; Rahn, 2003].
- Long duration of anesthesia necessary for some dentoalveolar surgical procedures [Shabazfar et al., 2014].

### **2.2.5. Disadvantages of IANB**

- A wide area of anesthesia (not necessary for localized procedures e.g. treatment of a single tooth) [Dirnbacher, 2002].
- A concomitant anesthesia of the tongue and the lower lip is not comfortable for many patients and could be dangerous in children and handicapped patients [Chi et al., 2008].
- The absence of reliable intraoral landmarks for the injection technique [Rahn, 2003].
- A high failure rate of the anesthesia of 10% to 26% [Kaufman et al., 1984; Heizmann, 1987; Rood, 1988].
- A long latency time of anesthesia (3 to 5 minutes) [Malamed, 1997; Dirnbacher, 2002; Shabazfar et al., 2014].

- A high risk of intravascular injection or injury of the blood vessels with a positive aspiration (11%-30%, highest of all intraoral injection techniques) [Weber, 1981; Lipp and Daubländer, 1998; Evers and Haegerstam, 2000].
- A high risk of nerve Injury [Pogrel, 2007].

#### **2.2.6. Complications of IANB**

Even if the IANB is considered as a gold standard technique of local anesthesia in the lower jaw, a significant number of cases with unwanted side effects and complications related to this technique have been reported in the literature [Rood, 1988; Pogrel and Thamby, 2000; Pogrel, 2007; Choi et al., 2009; Gaffen and Hass, 2009; Chevalier et al., 2010; and others]. Here, some of these are listed:

##### **2.2.6.1. Failure of the anesthesia**

The reported failure rate of the IANB ranges between 10% and 26% [Kaufman et al., 1984; Heizmann, 1987; Rood, 1988]. This relatively high rate of failure is, in particular, due to the fact, that the mandibular foramen is neither clinically palpable nor can be exactly localized [Rahn, 2003]. The needle is guided by variable unreliable intraoral anatomical structures, which occasionally result in the application of the anesthetic solution far away from the nerve trunk. In addition, the position of the mandibular foramen changes with skeletal growth both in craniocaudal and anteroposterior directions [Nicholson, 1985].

Technical errors such as inaccurate injection technique, lack of knowledge of the anatomy, lack of experience and needle deviation are reported as the most frequent causes of failure [Madan et al., 2002]. In addition to the technical errors, anatomical variations, inflammation or infection in the site of injection, inactive anesthetic solution and extremely anxious patients are other possible causes of failure of the IANB [Boronat López and Peñarrocha Diago, 2006].

Concerning the anatomical variations, four of these were described, namely the presence of a retromandibular foramen, an accessory mylohyoid nerve, a bifid mandibular nerve, and a contralateral innervation of the anterior teeth [Desantis and Liebow, 1996; Boronat López and Peñarrocha Diago, 2006]. The presence of a retromolar foramen is reported with a prevalence of 7.7% [Sawyer and Kiely, 1991]. In 0.4% of cases, the inferior alveolar nerve presents two or even three branches

passing through accessory foramina [Boronat López and Peñarrocha Diago, 2006]. Langlais et al. [1985] recorded in a series of 6000 panoramic X-ray, 57 bifid canals (0.95%). These findings indicate that bifid canals are not so unusual.

#### **2.2.6.2. Nerve injury**

Prolonged and possibly permanent alterations in sensation due to nerve injury could occur after dental injections. The nonsurgical cases of nerve injury in dentistry are almost exclusively related to IANB injection and appear to affect the lingual nerve 60%-70% more frequently than the inferior alveolar nerve [Malamed, 1997; Pogrel and Thamby, 2000; Gaffen and Hass, 2009]. A combination of injury of both nerves is also possible [Pogrel and Thamby, 2000].

According to Pogrel [2007], permanent nerve involvement after IANB may occur in about 1 of 20.000-850.000 patients. The lingual nerve is more prone to injury as it lays only 3 to 5 mm away from the mucosa and the intraoral landmark for IANB (the pterygomandibular raphe). When the mouth is opened, the lingual nerve is held taut within the interpterygoid fascia, and because of its fixation, it is prone to be injured by the needle [Harn and Durham, 1990; Hillerup and Jensen, 2006; Smith and Lung, 2006].

The exact biological mechanism of nerve injury remains the subject of debate in the literature. The most common and most tenable theories are direct trauma to the nerve with the needle, intraneuronal hematoma, and local anesthetic neurotoxicity [Smith and Lung, 2006]. An intraneuronal injection of the local anesthetic is more probable with a second injection since the piercing of the already anesthetized nerve is not noticed by the patient.

#### **2.2.6.3. Injury to blood vessels and inadvertent intravascular injection**

By injection in the highly vascularized area, the risk of injury to the blood vessels and/or intravascular injection is relatively high [Rood, 1972]. The rate of the inadvertent vascular contact during IANB injection ranges between 11% and 20% [Weber, 1981; Lipp and Daubländer, 1998; Taghavi Zenouz et al., 2008]. Evers and Haegerstam [2000] claimed a positive aspiration rate of more than 30%.

An intravascular injection can result in severe systemic intoxication. In patients with anticoagulation therapy and those with bleeding disorders, the mere infringement of a

blood vessel could result in serious bleeding into the medial pterygoid muscle or the pterygomandibular space and the surrounding soft tissue [Carter et al., 2003], potentially even leading to a fatal result.

#### **2.2.6.4. Muscle injury and trismus**

Injury of the medial pterygoid muscle, particularly by repeated injections, could result in the development of hematoma and trismus. The injured muscle becomes tender, producing discomfort when opening the mouth. During a period of sleep, when the muscles are not in use, the muscles go into spasm leaving the patient with significantly reduced mouth opening in the morning [Malamed, 1997; Wright, 2011].

#### **2.2.6.5. Needle breakage**

Material errors, incorrect injection technique in a hurry and a sudden or unexpected movement of the patient during the injection could result in breakage of the needle [Daubländer and Kämmerer, 2014]. This complication became rare with the significant improvement of material properties of the needles and the use of disposable needles that are not to be resterilized. However, all reported cases of needle breakages occurred mostly in cases of IANB [Ethunandan et al., 2007; Pogrel, 2009].

#### **2.2.6.6. Self-inflicted soft tissue injury**

The duration of the anesthesia after a successful nerve block generally exceeds by far the time required for a routine dental treatment. During this time, the responsiveness of the patient is decreased. The area anesthetized is relatively wide and this is associated with an increased risk of an accidental bite injury to the lip and/or tongue, especially by children und handicapped patients [Davidson and Craig, 1987; Bendqude et al., 2001; Chi et al., 2008].

#### **2.2.6.7. Transient facial nerve paralysis**

Transient facial nerve palsy as a complication of the IANB is a rarely reported incident. The most common cause of this complication is the deposition of the local

anesthetic too far posteriorly in the body of the parotid gland i.e. close to the facial nerve [Chevalier et al., 2010; Tzermpos et al., 2012].

### **2.3. Intraligamentary anesthesia (ILA)**

#### **2.3.1. Instruments for ILA**

Even if ILA can principally be administrated by using the conventional aspiration syringes [Walton and Abbott, 1981], special syringe systems for intraligamentary injection have been developed and are preferable. Injection systems for ILA should provide a mechanism for amplifying the injection pressure applied by the dentist in order to overcome the encountered resistance when injecting the anesthetic solution into the dense periodontal ligament space. This should also give the dentist the opportunity to feel the individual anatomic variation and to adjust the applied injection pressure accordingly.

##### **2.3.1.1. Mechanical injection systems**

In order to create a pressure required to overcome the interstitial resistance of the periodontal ligament tissues for injection of the anesthetic solution, different syringe systems have been developed by different manufacturers and are available on the market since the late 1970s.

###### **2.3.1.1.1. Pistol type syringes**

Via an integrated lever mechanism, these syringe systems amplify mechanically the injection pressure applied by the dentist. Examples for these syringe types are Peri-press® (Resista, Omegna, Italy) and Ligmaject® (Henke-Sass Wolf, Tuttlingen, Germany). However, with these syringe systems, the dentist cannot feel the individual anatomical variations of the periodontium and adjust the injection pressure accordingly. A mechanical amplification of the injection pressure without pressure limiting mechanism allows the local anesthetic to be injected rapidly into the periodontal ligament space – and hence with higher pressure than required. In accordance, the recorded injection pressure applied by these systems varies from 10 to 344 Newton [Leilich et al., 1985].

In order to get a better control on amplifying the injection pressure, a pistol type syringe with an integrated pressure limiting mechanism was developed in the mid-1980s [Rahn et al., 1987]. This syringe system has been brought onto the market by Hoechst (Sanofi-Aventis, Frankfurt am Main, Germany) under the name of Ultraject® (Figure 2). The Ultraject® syringe consists of a screw-able holder for the local anesthetic cartridge with a plastic protection tube and a fixture for attachment of the screw-able needle, a body of the syringe consisting of a toothed piston rod and a pawl for locking the piston rod, a trigger lever and a handle with the mechanism of pressure limitation. The automatic pressure limiting mechanism ensures that the applied pressure does not exceed 120 N. When pulling the trigger lever too quickly, the pressure transmission will stop automatically.



Figure 2: Ultraject® syringe (Sanofi-Aventis)

#### 2.3.1.1.2. Penholder grip syringes

In 1984, Bayer and Ronvig (Daugaard, Denmark) introduced the penholder grip syringe systems [Zugal, 2001]. In these syringe systems, a wing mounted laterally on the handle of the syringe adopts the function of the trigger lever. This wing transfers the applied force via an integrated multistage lever system to the piston rod and then to the cartridge. Examples of these systems are Citoject® (Heraeus-Kulzer, Hanau, Germany) and Paroject® (Ronvig, Daugaard, Denmark) syringes.

Instead of the usual 0.2 ml of local anesthetic released by each pull on the trigger lever of the pistol type syringe systems, only 0.06 ml of anesthetic solution is released by each stroke on the dosing lever (wing) of these syringe systems.

Therefore, in order to apply the required amount of about 0.2 ml local anesthetic per injection site, the wing must be squeezed three times per each injection site. The duration of the injection and the amount of the injected local anesthetic can consequently be better controlled and adjusted by the dentist.

#### **2.3.1.1.3. Dosing wheel syringes**

With this syringe system, the injection pressure is amplified by means of a dosing wheel. The force exerted on the dosing wheel is amplified by a ratio of 5.5:1, due to the different sizes of the wheels, and transmitted directly by turning the dosing wheel from back to front on the toothed piston rod. With each rotational movement of the dosing wheel, 0.1 ml of local anesthetic is released. To apply the desired 0.2 ml per injection point, two rotational movements of the dosing wheel are necessary [Glockmann and Taubenheim, 2010]. This syringe system enables to feel the individual tissue resistance directly with thumb or index finger [Tobien and Schulz, 2000]. An example of this syringe system is the SoftJect® (Henke-Sass Wolf, Tuttlingen, Germany).

#### **2.3.1.2. Electronically controlled injection systems**

In addition to the mechanical injection systems for the manual administration of ILA, electronically controlled injection systems were developed in the last two decades. The first computer-controlled local anesthetic delivery system (C-CLAD™) for periodontal ligament injection “The Wand®” (Milestone Scientific Inc., New jersey, USA) was introduced in 1997, and has been followed by other systems from different manufacturers, such as CompuMed® (Utah Medical Products, Inc., Utah, USA), CompuDent®, and STA®- System (Milestone Scientific Inc., New Jersey, USA) [Von Haussen, 2011].

With the new technology of computer-controlled local anesthetic delivery systems, the injection time was adjusted to the measured resistance of the periodontal tissues at the site of the injection. The local anesthetic is administered into the periodontal ligament space very slowly via a foot pedal or manually controlled by means of the hand piece [Shepherd et al., 2001; Hochman et al., 2006, 2007]. With a similar application mode, the various systems differ mainly in the number of selectable



application programs, the control by hand or foot, as well as the display options regarding the application process by LED or digital visualization.

In the newer devices such as the STA™ system with the STA-Wand® hand piece (Milestone Scientific Inc., New Jersey, USA), in addition to extended speed modes, an additional mode for computer-controlled information about the pressure prevailing in the periodontal tissue during injection (dynamic pressure sensor technology (DPS)) is offered. The pressure is tested repeatedly in a second and can be read on the display. The information provided by the DPS is to give the clinician indications of the tissue properties, the interstitial pressure and thus liquid absorption capability of the tissue [Hochman et al., 2007].

### **2.3.1.3. Needles**

The selection of adequate needles for the periodontal ligament injection is of paramount importance. The sulcus between tooth and alveolar bone is extremely narrow; for this reason, the external diameter of the injection needle used should not be larger than 0.3 mm (= 30 G). In order to keep the injection pressure as low as possible, the inner diameter of the needle should be as large as possible in relation to the outer diameter. The tip of the needle should have an extra-short bevel to prevent it from bending while in contact with the tooth, which would increase the resistance. Current recommendation is to use system-adapted injection needles, 0.3 mm (= 30G) with a length between 12 and 16 mm with the necessary stiffness to prevent bending during insertion [Endo et al., 2008].

### **2.3.2. Technique of ILA**

The local anesthetic solution is injected under controlled high pressure into the periodontal ligament space between root and alveolar bone. At least one injection point is generally to be defined for each root of the tooth to be anesthetized. Principally it can be injected at any point along the gingival sulcus; however, the mesiofacial and distofacial points are more favorable, as they are easily accessible [Heizmann and Gabka, 1994]. If repeated injections are required, another point of injection has to be selected; repeated injections at the same point could cause tearing and detachment of the periodontal ligament fibers [Plagmann and Jagenow, 1984]. The needle is introduced through the gingival sulcus, at an angle of 30-40

degrees to the long axis of the tooth, and is advanced 2-3 mm into the periodontal ligament space between root and alveolar bone [Dreyer et al., 1983; Daubländer and Kämmerer, 2014] (Figure 3). Further advance of the needle into the periodontal ligament space beyond this depth would usually not be possible. The bevel of the needle tip should be directed towards the alveolar bone and away from the root surface. This needle position permits the anesthetic solution to spread into the bone instead of squirting out of the ligamental space. To reduce the injection pain, a few drops of local anesthetic solution can be deposited simultaneously with or right before insertion of the needle. The handle of the syringe is then squeezed firmly until backpressure is achieved. A resistance to the injection must always be present, if no resistance is felt, the position of the needle might be incorrect; this has to be controlled and changed. The injection pressure is sustained to deposit the local anesthetic solution slowly into the dense periodontal ligament space.

According to the actual state of art, 0.2 ml of local anesthetic is to be injected for each root over at least 20 seconds. At two rooted teeth, one injection is required for each root, wherein the injection time for the second injection should be a little longer (more than 20 seconds). At three-rooted teeth, three injections are required (one for each root) and the injection time for the third injection should be obviously longer (more than 25 seconds) [Endo et al., 2008; Bender and Taubenheim, 2014].

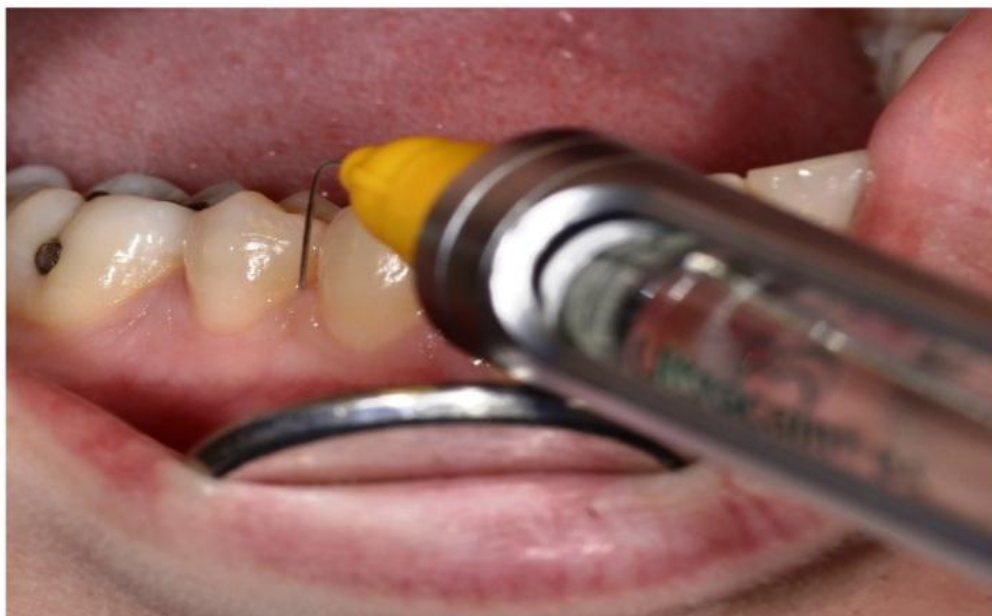

Figure 3: Intraligamentary injection

The injection time has a significant influence on the pressure required to overcome the tissue resistance during injection of a defined amount of local anesthetic. Obviously, the injected volume is slowly absorbed by the tissue, so that the injection resistance decreases gradually [Tobien and Schulz, 2000]. Due to the incompressibility of liquids and the narrowness of the available periodontal ligament space into which the anesthetic solution is to be injected, a too rapid injection can lead to deflection of the tooth in the alveolus and to the clinical symptoms of feeling of elongation, pressure pain, and pre-contact [Huber and Wilhelm-Höft, 1988; Zugal, 2001].

### **2.3.3. Mechanism of action of ILA**

Formerly, it was assumed, that the intraligamental injection forces the local anesthetic solution primarily along the periodontal ligament space until it reaches the apical area of the root producing local anesthesia of only one tooth. This assumption has been disproved on the basis of animal experiments conducted by several authors [Walton and Garnick, 1982; Garfunkel et al., 1983; Plagmann and Jagenow, 1984; Tagger et al., 1994; Kämmerer et al., 2012; and others]. Histological and radiological studies show a little or no solution in the periodontal ligament space after injection of ink containing local anesthetic solution and local anesthetic containing radiologic detectable substances in the periodontal ligament space of the experimental animals. Today, there are three theories about the working mechanism of the ILA:

#### **2.3.3.1. Vascular distribution**

Under the influence of the relatively high injection pressure, the local anesthetic solution injected into the periodontal ligament space is forced through the lamina cribiformis into the alveolar bone and its blood vessels. It finally reaches the dental pulp via the arterial blood supply and exerts its action on the nerve endings in the dental pulp [Castagnola et al., 1982; Erlemeier, 1991; Müller and Henne, 1991].

#### **2.3.3.2. Medullary distribution**

The injected local anesthetic solution is primarily forced into the bone marrow space of the alveolar bone through perforations formed by the blood vessels (nutrient

canals); from this point, it spreads further through the bony canals and reaches the periapical area of the root and exerts its action extra-pulpally [Smith and Pashley, 1982; Smith and Walton, 1983; Müller and Henne, 1991; Tagger et al., 1994].

#### **2.3.3.3. Combination of vascular and medullary distribution**

Today, it is believed that the spread of the injected solution into its working site occurs through a combination of the two distribution patterns mentioned above (Figure 4). Accordingly, the bulk of the injected solution is forced laterally through the cribriform plate into the marrow space and the blood vessels. From there, the solution spreads to adjacent teeth and structures and enters the systemic circulation [Walton and Garnick, 1982; Dreyer et al., 1983; Garfunkel et al., 1983; Smith and Walton, 1983; Plagmann and Jagenow, 1984; Müller and Henne, 1991].

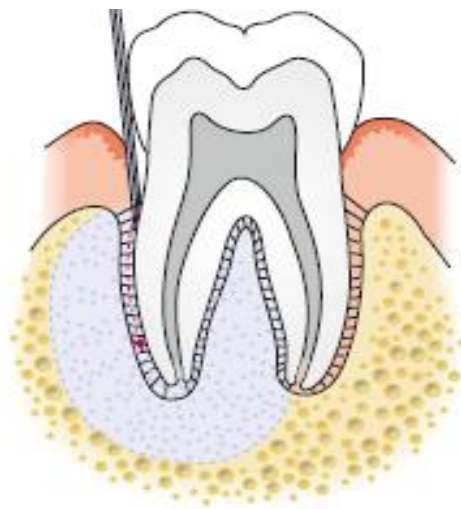

Figure 4: Mechanism of action of ILA [from Daubländer and Kämmerer, 2014]

#### **2.3.4. Limitations of ILA**

Although it is possible to extend the area and the duration of the anesthesia by increasing the number of injections, the ILA is not suitable for prolonged and extensive dentoalveolar surgical procedures due to the limited spread of the injected anesthetic solution and the relatively short duration of anesthesia [Endo et al., 2008; Zugal and Taubenheim, 2008]. Also, just a very limited soft tissue anesthesia – if any - is obtained.

### **2.3.5. Anesthetic profile of ILA**

The local anesthetic effect is limited to the target tooth, its supporting tissues, and in a limited extent to the neighboring mesial and distal teeth without concomitant anesthesia of the tongue, lips, and cheeks. The amount of local anesthetic solution required to produce the intended anesthesia is very small in comparison to the other conventional techniques of local anesthesia. This makes it possible to undertake dental treatment at many teeth in the same appointment without substantially increasing the risk of overdosing and systemic intoxication [Heizmann and Gabka, 1994; Endo et al., 2008].

The anesthetic effect starts immediately after the injection and the maximum anesthetic effect is reached within 30 seconds after the injection [Gray et al., 1987; Plagmann, 1987; Zugal, 2001]. This very rapid onset of action enables the dentist to evaluate the success of the anesthesia and to begin the treatment immediately. The duration of the anesthesia after the periodontal ligament injection is approximately 30-45 minutes; this time is usually sufficient to perform the majority of dental treatments. At the same time, the patient can resume his normal activities shortly after completion of the treatment. The speech and chewing functions are minimally affected and the risk of postoperative bite and burn injuries decreases drastically.

Due to injection into the periodontal ligament space, there is practically no risk of damage to the blood vessels and/or the nerve; therefore, it is not mandatory to inform the patient about these complications and to obtain an informed consent as it is in the case of nerve block anesthesia [Kaltenbach et al., 2006].

### **2.3.6. Indications of ILA**

Generally, ILA can be used as a primary or as a supplementary method for treating the individual teeth in the upper and lower jaws. Indications of the ILA include:

- Minimal invasive dental surgical procedures [Malamed, 1982; Faulkner, 1983; Kaufman et al., 1983; Edwards and Head, 1989; Heizmann and Gabka, 1994; Dumbigue et al., 1997, Kämmerer et al., 2010].
- All dental restorative therapeutic measures including removal of caries, preparation for crown and bridge [Zugal, 2001; Kämmerer et al., 2015].
- Endodontic therapy especially when subsequent injections are required while using rubber dam [Weber et al., 2006; Glockmann et al., 2007].

- Completion of anesthesia in case of incomplete anesthesia or failure of other methods of local anesthesia [Heizmann and Gabka, 1994].
- Periodontal therapy (closed periodontal therapy measures) [Prothmann et al., 2009].

**ILA offers particular advantages in:**

- Differential diagnosis of unclear pulpal pain. Since with ILA every tooth can be anesthetized individually, sensitivity can be tested tooth by tooth [Simon et al., 1982; Littner et al., 1983; Garfunkel et al., 1985; Zugal et al., 2005].
- Dental treatment of patients with cardiovascular diseases, as only a small amount of local anesthetic solution is required [Garfunkel et al., 1985; Endo et al., 2008].
- Dental treatment of patients with hemorrhagic diathesis and those under anticoagulant therapy [Stoll and Bührmann, 1983; Stoll et al., 1986].
- Treatment of children and patients with mental disabilities [Anand et al., 2005]; the pain of injection is virtually very slight due to the fine needles used [Einwag, 1982]. Additionally, the risk of postoperative bite trauma is reduced due to the short duration of the anesthesia and the absence of the concomitant anesthesia of lip and tongue [Davidson and Craig, 1987].
- Treatment of patients with dental fear and anxiety. A minimal injection pain, immediate onset of profound anesthesia with a limited regional extension plays an important role in the reduction of fear and anxiety of the patient [Adubae et al., 2016].

Using instruments and anesthetics that comply with the state of art and science, ILA - in the hand of an experienced dentist - is a method of local anesthesia, which is applicable for the above-mentioned indications [Bender and Taubenheim, 2014].

**2.3.7. Contraindications of ILA**

In addition to the conditions that make local anesthesia contraindicated in general, ILA is relatively contraindicated in:

- Patients with risk of endocarditis due to the risk of bacteremia [Rahn et al., 1986].
- Immunocompromised patients.

- Ankylosed teeth.

### **2.3.8. Complications of ILA**

Certain complications and unwanted side effects in connection with the ILA had been supposed by some authors [Phillips, 1943] and summarized by Giovannitti and Nique [1983]. The supposed complications were then studied systematically in the following years by many researchers. The results of some of these studies will be discussed in the following paragraphs.

#### **2.3.8.1. Damage to periodontal tissues**

It was claimed that insertion of the needle through the junctional epithelium and injection of the local anesthetic solution under high pressure into the periodontal ligament space, causes inflammation and permanent damage to the periodontal tissues [Phillips, 1943]. However, the results of the many histological studies conducted by many investigators showed that only minimal histological effects in the periodontium were induced by intraligamental injections; these changes regenerated within a short time. The authors concluded that the ILA is a safe and reliable method with only minimal transient and reversible inflammatory changes in the periodontal tissue [Walton and Garnick, 1982; Fuhs et al., 1983; Galili et al., 1984; Anneroth et al., 1985; Müller and Henne, 1991; Tagger et al., 1994; and others].

Only repeated injections at the same site can cause tear and detachment of the periodontal ligament fibers from the bone [Plagmann and Jagenow, 1984]. For this reason, it is advised that the needle is inserted at another point when a second injection is required.

The effects of the intraligamental injection on the pulpal tissue were studied by Lin et al. [1985]; neither pathological changes such as degeneration and/or ischemic necrosis, nor inflammation in the pulps of the examined teeth were observed in that study. The harmlessness of intraligamentary injection on pulpal tissues was confirmed by studies conducted by many other investigators [Gray et al., 1987; Grund et al., 1992; Torabinejad et al., 1993].

### **2.3.8.2. Bone and root resorption**

Reversible bone and root resorptions, confined to the area of the crestal bone, with a complete healing within 25 days after intraligamental injection were reported in animal models [Walton and Garnick, 1982]. Pertot and Déjou studied the histological effect of the mere needle insertion and of the injection of a saline solution on bone and root resorption at 105 sites in the periodontium of five dogs, with observation periods of 7, 25 and 45 days. The injections were made with a specially designed syringe equipped with a miniaturized force transducer. They observed that, at 7 days, both needle penetration and the injection of saline solution resulted in increased osteoclastic, odontoclastic activity and in bone and root resorption. The extent of bone resorption was greater after injection of saline solution than that after the mere needle penetration without injection. At 25 and 45 days, healing had occurred in all cases. These findings suggest that the injection pressure is sufficient to initiate osteoclastic but reversible bone resorption [Pertot and Déjou, 1992].

### **2.3.8.3. Soft tissue necrosis**

In a clinical study conducted by Kaufman et al. [1983], only one case of mucosal inflammation with marginal necrosis was observed after administration of ILA to 258 teeth in a total of 187 patients. Five other patients reported a post-operative pain that lasted for 2 days after treatment. In another clinical study conducted by Zugal et al. [2005], no case of necrosis or any other tissue damage was observed in 205 documented cases of ILA. Glockmann et al. [1997] could not find a significant increase in the probing depth, within 3 months after periodontal ligament injection.

### **2.3.8.4. Impaired wound healing (dry socket)**

Tsirlis et al. studied the frequency of occurrence of dry socket after extraction of mandibular molars under ILA and IANB. In that study, 305 extractions of mandibular molars in two groups of patients were documented. The first group of patients received IANB, whereas the second group received ILA as local anesthetic technique. Eleven cases of dry socket were observed, five of which were in the first group and six in the second group. The authors concluded that the use of ILA did not result in a higher incidence of dry socket than did IANB [Tsirlis et al., 1992]. In another study, Heizmann and Gabka compared ILA, IANB and infiltration anesthesia



in the extraction of mandibular and maxillary teeth. The results of that study showed no significant differences in the frequency of occurrence of dry socket after the three local anesthetic methods [Heizmann and Gabka, 1994].

#### **2.3.8.5. Bacteremia**

Numerous dental therapeutic measures, including the periodontal ligament injection, can trigger a bacteremia. A sepsis due to promoting bacteria through the injection needle into the tissue and into the blood stream can possibly occur. Walton and Abbott [1981] clarified that this is probably the case in intraligamental injections, but in no greater extent than with other dental treatments. The resulted bacteremia is usually transient. In 1986, Rahn et al. published the results of a study on the incidence of bacteremia after ILA. They found that the incidence of bacteremia is significantly higher after ILA when a high injection pressure is used. The risk of endocarditis represents, according to Rahn et al. a clear restriction to the use of ILA. Though, studies proving the clinical relevance are lacking.

#### **2.3.8.6. Unwanted side effects**

Unwanted clinical side effects such as postoperative discomfort, pressure pain, a sensation of tooth elongation and pre-contact after abatement of the ILA have been described in various publications [Malamed, 1982; Faulkner, 1983; Kaufman et al., 1983; Plagmann, 1987]. The causes of these unwanted effects often lay in the fact, that the injection of the anesthetic solution did not take place under adequate consideration of the individual anatomical conditions of the patient.

In their study, Huber and Wilhelm-Höft showed that the tooth could move in its socket under the influence of the high injection pressure. During intraligamentary injection, a volume of liquid is pumped under pressure into a chamber, which is already filled completely. Since liquids are incompressible, an extension of the alveolus or a shift of periodontal fluid cushion under the influence of the high injection pressure comes primarily into consideration [Huber and Wilhelm-Höft, 1988]. In order to avoid these unwanted effects, the anesthetic solution should be injected slowly, giving time for the anesthetic solution to be absorbed by the tissue [Zugal et al., 2005]. By increasing the injection time, the injection pressure required to overcome the tissue resistance decreases gradually.

### **2.3.8.7. Hypoplasia of permanent teeth**

The pressure used during intraligamental injection to primary teeth can force the anesthetic solution into the underlying tooth germs of the permanent teeth [Brännström et al., 1982]. In an experimental animal study, Brännström et al. [1984] noticed cases of enamel hypoplasia and/or hypomineralization in a total of 15 permanent teeth after application of ILA to 16 primary teeth of two monkeys using the Peripress® injection syringe. Based on this result, Brännström suggested that great care should be taken, when using ILA on primary teeth close to developing permanent teeth. However, the diffusion of the injected solution into germs of permanent teeth could not be observed after periodontal ligament injection of ink containing local anesthetic solutions to six primary teeth of two young sheep [Kämmerer et al., 2012], and at 58 sites to primary teeth in five dogs [Tagger et al., 1994]. To our knowledge, such effects on permanent teeth have never been reported in humans yet.

## **3. Aims of the study**

### **3.1. Problem and objectives**

Considering the relatively high failure rate and the risk immanent in the technique of IANB, as well as the legal demand of informing the patient about possible risks of an indicated health measure and about available alternatives [Bluttner and Taubenheim, 2009], the question arises whether the ILA as a primary anesthetic technique can meet the requirement of a complete and patient-friendly local anesthetic technique and whether it can be considered as a valid alternative to the conventional IANB for extraction of mandibular posterior teeth.

In this study it was to be tested whether the technique of ILA administered with pistol type syringes with pressure limiting mechanism can be considered as a valid alternative to the IANB for extraction of mandibular posterior teeth. The primary objectives were particularly to evaluate the difference in pain experienced by the patients during treatment as well as the efficacy of the local anesthesia (complete/sufficient vs. insufficient/no effect) and the need for second injection based on the outcome of treatment and the degree of discomfort associated with the extraction procedure. Of secondary interest were the differences in the amount of

anesthetic solution, latency time of the anesthesia, duration of treatment and duration of local numbness. A further objective was to clarify whether impaired wound healing after tooth extraction (dry socket) was more frequent after ILA than following IANB. The precise, very complex influence between systemic diseases of the patients and the wound healing processes or the frequency of wound healing disturbance were not to be examined here, but it was rather to ascertain whether more wound healing disturbances occur after ILA.

## **4. Materials and methods**

### **4.1. Design of the study**

This present study was a prospective, randomized comparative clinical trial conducted in the Department for Oral and Plastic Maxillofacial Surgery of the University Medical Centre Rostock, Germany after approval of the local ethics committee of the Faculty of Medicine- University of Rostock (No A 2014-0129) in a period of 12 months from April 2014 to April 2015. Two different techniques of dental local anesthesia (ILA and IANB) were compared with the help of several parameters.

### **4.2. Materials**

#### **4.2.1. Patients**

Adult patients of both sexes with one or more mandibular posterior teeth indicated for extraction were selected for this study. These patients were referred to the Department for Oral and Plastic Maxillofacial Surgery of the University Medical Centre Rostock for dental extractions. The patients were assigned randomly into those who received ILA and those who received IANB as local anesthetic technique for the indicated dental extraction. In the cases of bilateral dental extraction, ILA was administered first on one side and tooth was extracted on this side. After completing the treatment and documentation on this side, IANB was then administered on the other side and another tooth was extracted. Although this could potentially affect the patients' perception of pain during subsequent procedures, it was reasoned that this would be the more logical approach since the claimed onset of ILA is immediate.

##### **4.2.1.1. Inclusion criteria**

Included in the study were patients of both sexes at least 18 years old and with clinical indication for dental local anesthesia because of indicated extraction of one or more mandibular posterior teeth. Only teeth requiring simple extractions were included in the study.

When more than one tooth on one side of the mandible was to be extracted under ILA, each tooth was considered as independent sample, as each tooth requires its own ILA anesthesia. When, however, many teeth on one side to be extracted under IANB, only one tooth that best fulfils the inclusion criteria was considered. After

injection and extraction of this tooth was accomplished and documented, the other tooth/teeth was/were then extracted but not included in the study.

#### **4.2.1.2. Exclusion criteria**

Exclusion criteria were the following: patients under 18 years of age, incapacitated patients, patients with contra-indications for any of the components of the anesthetic solution (allergy to articaine, epinephrine, and sulfite), patients with American Society of Anesthesiologist classification > 2, chronic or simultaneous taking of psychotropic or anti-inflammatory (NSAD) drugs in temporal context with the dental treatment, lack of compliance, pregnancy, as well as infection in the area of injection. Teeth with acute apical infections or drainage of pus from the gingival sulcus or surrounding tissues, and teeth with more than 0.5 mm mobility in any direction were not included in the study.

#### **4.2.2. Materials for IANB**

Inferior alveolar nerve blocks were administered using disposable syringes (BD Discardit II™, 5 ml; Becton, Dickinson and Company, New Jersey, USA) and 25 gauge/42 mm needles (Sterican®; B. Braun Melsungen AG, Melsungen, Germany). The local anesthetic agent used for IANB was Ultracain D-S 2 ml ampoules (articaine 40 mg/ml plus suprarenin 0.006 mg/ml; Sanofi-Aventis GmbH, Frankfurt am Main, Germany).

#### **4.2.3. Materials for ILA**

For the administration of ILA, pistol-type syringes with built-in safety mechanism for limiting the mechanical pressure (Ultraject®; Sanofi-Aventis GmbH, Frankfurt am Main, Germany) and 30 gauge short bevel/16 mm needles (Heraeus Kulzer GmbH, Hanau, Germany) were used. The local anesthetic agent used for ILA was Ultracain D-S 1.7 ml cartridges (articaine 40 mg/ml plus suprarenin 0.006 mg/ml; Sanofi-Aventis GmbH, Frankfurt am Main, Germany).

#### **4.2.4. Data collection**

Prior to the actual treatment, the purposes, nature of the study as well as the intended procedure and its possible complications were explained to the patients and

a written consent was obtained from each patient. A copy of the study information and the consent form was given to each patient.

For data collection, an evaluation sheet was created, which was divided into questions to be answered both by the dentist and the patients. The evaluation sheet was divided into four parts. The first part was to be filled out in the first appointment and involved the patient's personal data such as name, birth date, sex, weight, height and telephone number as well as the name of the dentist and the date of treatment. The medical and dental histories, as well as the history of drug ingestion were collected and noticed in this part. It was particularly asked if the patient took analgesic or sedative drugs and whether allergic reaction to local anesthetics or to the stabilizers contained in the solution was occurred in the past. At the second appointment and before the beginning of the actual treatment, the data collected at the first appointment were always controlled and updated. At this appointment, each patient was asked, whether he/she had questions in relation to the study and the agreement of the patients to participate in the study was reassured.

The second part of the evaluation sheet was to be filled out by the dentist and involved the statement of the tooth to be extracted, local anesthetic technique used, time of injection, and the amount of injected solution. The onset time of anesthesia, quality of the anesthesia obtained, need for second injection, observed signs of contact with the nerve or the blood vessels, as well as the exact time of the start of extraction procedure were also noticed by the dentist.

In the third part were questions to be answered by the patients and dealt with the quality of the anesthesia obtained, need for second injection and the intensity of the pain perceived during injection and extraction procedure. The fourth part was to be filled out one day after tooth extraction (some time via telephone) and involved the duration of anesthesia. The other points of this part were to be filled out at the third appointment 3-5 days later and involved signs of possible complication such as dry socket. This evaluation sheet is shown in the appendix (Page: 83).

### **4.3. Methods**

#### **4.3.1. Method of administering IANB**

The technique used for IANB was the intraoral conventional direct method described previously in paragraph 2.2.1.1 page no. 7-8.

#### **4.3.2. Method of administering ILA**

First, the local anesthetic cartridge with the protective tube was inserted into the cartridge holder. The pawl was depressed and the piston rod was withdrawn from the syringe body until it stopped. Then, the cartridge holder was screwed onto the syringe. Next, a thin needle was placed onto the cartridge holder and screwed tightly. The trigger lever of the syringe was pressed slightly until few drops of anesthetic solution appeared at the needle tip. The syringe was now ready for injection.

The injections were carried out using the injection technique described previously in paragraph 2.3.2 page no. 16-18.

#### **4.3.3. Documentation of anesthetic effect**

The exact time of injection, the technique of local anesthesia used and the injected amount of local anesthetic solution were noticed by the dentist in the evaluation sheet. Immediately after injection, each patient had to determine how painful the injection was using 11- points segmented numeric rating scale (NRS). Each patient had to select a number from a horizontal bar (0-10; 0 = no pain, 10 = extreme pain) that best reflected the intensity of his pain. In order not to influence the perception of the injection pain by the patient, no topical anesthesia was used.

Signs of complications during and immediately after the injection and the incidence of a positive aspiration were also noticed in the evaluation sheet. The appearance of blood in the syringe or the appearance of reddish discoloration of the anesthetic solution after aspiration was categorized as a positive aspiration. When positive, the anesthetic solution was discarded and the injection was repeated with a new anesthetic solution and a new needle. As criteria of direct nerve contact, subjective experience of a sudden strike of pain by the patient during the advance of the needle in the soft tissue and/or the experience of prolonged hypoesthesia or dysesthesia after treatment was defined.

Numbness was tested with a dental probe on the gingiva immediately after the injection and further each 10 seconds in case of ILA and each 30 seconds in case of IANB till full numbness was declared and the time of onset of the anesthetic effect was noticed.

The extraction procedures started with elevators and forceps. The time of beginning the treatment was also noticed in the evaluation sheet. The subjective quality of the

anesthesia was documented both by the dentist and the patient in separated fields using a Likert- scale (complete, sufficient, insufficient and no effect). The anesthesia was assessed as complete when it was possible to remove the tooth without pain and discomfort. The ability to remove the tooth with mild but tolerable pain and discomfort was assessed as sufficient anesthesia. Anesthesia was assessed as insufficient when anesthetic effect was reported by the patient subjectively but the tooth could not be extracted successfully with tolerable pain and discomfort. A severe pain during the extraction with an absence of subjective anesthetic effect was assessed as no anesthetic effect. Cases of insufficient and no anesthetic effect after the first injection were considered as primary anesthetic failure. The patient had to decide on the basis of the remaining pain, whether a second injection was required. The need for a second injection was documented on the evaluation sheet.

When needed, the second injection was done using the same anesthetic technique as for the first injection. The time of the second injection and the injected amount of local anesthetic solution were also documented by the dentist. The subjective quality of anesthesia (complete, sufficient, insufficient and no effect) was documented again. If the anesthesia, after the second injection was still incomplete and the completion of the treatment without tolerable pain was not possible, a combination of the both anesthesia techniques was undertaken. These cases were considered as cases of secondary anesthesia failure.

After complete removal of the tooth, the socket was cleaned carefully, the sharp bony edges were removed and the time of the end of extraction procedure was documented. The treatment was finished with a placement of a piece of sterile gauze on the extraction wound. Patients were asked to remain seated for several minutes after completion of treatment and to evaluate the overall pain and unpleasantness of the entire treatment again using the 11- points segmented numeric rating scale (NRS). Postoperative instructions were given to the patient orally and in written form. Prescription of postoperative antibiotics was done in only few cases with a height risk of wound healing disturbances.

One day later, the patients were asked (sometimes via telephone) about the duration of soft tissue anesthesia and possible adverse effects.

The wounds were examined for signs of retarded healing (dry socket) at a second appointment within one week after tooth extraction. The criteria for the diagnosis of a dry socket were: empty alveolus, denuded bone surface being very sensitive to



probing, extreme pain that lasted more than 3 days after extraction and unpleasant taste and/or odor.

#### **4.3.4. Statistical methods**

For descriptive analysis of categorical data, absolute and relative frequencies were calculated. For continuous data, minimum, maximum, median and mean values, skewedness, quartiles and standard deviations were calculated. Categorical data were visualized via bar charts, consistent data via boxplots. For further explorative data analysis, Kolmogorov-Smirnov test was employed to test for a difference among ILA and IANB. In cases of p-values  $<0.05$ , Mann-Whitney-U test and in cases of p-values  $>0.05$ , Students' t-test for independent samples were employed. The influence of categorical variables was shown with chi-square tests and cross tables. A global significance level was chosen to 0.05. All analyses were carried out using SPSS Statistics version 22 (IBM, Armonk, NY, USA).

## **5. Results**

Two hundred sixty-six adult patients of both sexes (176 males, 90 females) with one or more mandibular posterior teeth (total number of teeth= 301) indicated for extraction were included in this study. 98 patients had co-morbidities (cardiovascular diseases n= 42; diabetes mellitus n= 16; malignant tumors n= 26; osteoporosis n= 7; dysfunction of thyroid gland n= 7). Beta-blockers were taken by 38 patients, anticoagulants by 14 patients, bisphosphonates by five patients, insulin by nine patients and seven took medications for dysfunction of the thyroid gland. Three of 266 patients reported acute dental pain before the treatment.

For data evaluation, patients were categorized into two evaluation groups (evaluation group I and II) based on whether only one or both anesthetic techniques were used in individual patients (unilateral or bilateral tooth extraction). Group I (patients n= 238, teeth n= 245) involved the patients who received randomly either ILA or IANB for indicated unilateral dental extraction while group II (patients n= 28, teeth n= 56) involved the patients who received both ILA and IANB because of indicated bilateral dental extraction (split-mouth).

ILA was compared with IANB in each evaluation group separately and the results in group I were then compared with that in group II (split-mouth).

### **5.1. Evaluation group I**

#### **5.1.1. Patients and teeth**

A total of 238 patients (153 males, 85 females) in the age group of 19-87 years (mean: 54.3; standard deviation (SD): 16.78) with height between 150-195 cm (mean: 173.4; SD: 9.23) and body weight between 45-156 kg (mean: 83.5; SD: 17.7) were included in this group. In these patients, a total of 245 teeth (Table 1) were extracted by one and the same dentist using the same local anesthetic agent (articaine with epinephrine 1:200.000) and the two different local anesthetic techniques. 105 teeth (in 98 patients) were extracted under ILA, whereas 140 (in 140 patients) were extracted under IANB following randomization (Figure 5).

Tooth number	Number of teeth extracted	Percent
34	15	6.12
35	21	8.57
36	31	12.65
37	52	21.23
38	4	1.63
44	13	5.31
45	21	8.57
46	39	15.92
47	46	18.78
48	3	1.22
<b>Total</b>	<b>245</b>	<b>100</b>

Table 1: Frequency of tooth extractions in group I

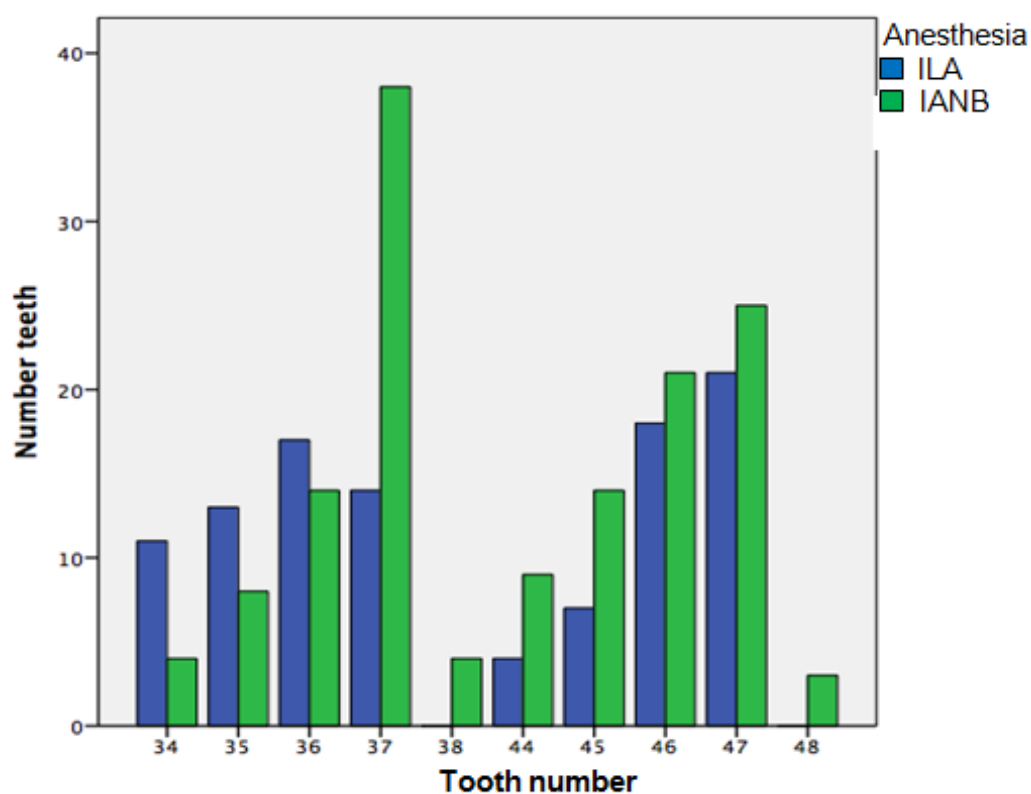


Figure 5: Bar charts showing number of extracted teeth per anesthetic technique

### 5.1.2. General parameters

#### 5.1.2.1. Age, height and body weight

The mean age of the patients who underwent tooth extraction under ILA was 56 years (SD: 15.6), whereas the mean age of the patients in whom IANB was used was 52.6 years (SD: 17.95). Comparing the means of age, no statistically significant difference could be found ( $p= 0.219$ ). The mean height of the patients was 172.58 cm (SD: 9.11) in case of ILA and 174.26 cm (SD: 9.34) in case of IANB. Concerning the mean body weight of the patients, it was 82.35 kg (SD: 16.37) and 84.73 kg (SD: 19.09) respectively (Table 2). When comparing the means of height ( $p= 0.259$ ) and of body weight ( $p= 0.406$ ) there was no significant statistical difference. Similarly, no statistically significant differences were found between ILA and IANB in relation to the existence of preoperative pain ( $p= 1$ ), and the reported general diseases ( $p= 0.285$ ).

	Anesthesia	Patient (n)	Mean	Standard deviation	Standard error of the mean value
Height (cm)	ILA	98	172.58	9.11	1.07
	IANB	140	174.26	9.34	1.01
Body weight (kg)	ILA	98	82.35	16.37	1.93
	IANB	140	84.73	19.09	2.06

Table 2: Mean height and body weight related to anesthetic technique

In accordance, the general parameters of patients treated with ILA and those treated with IANB were relatively homogenous and there were no significant statistical differences between ILA and IANB.

### 5.1.3. Parameters of the primary objectives of this study

#### 5.1.3.1. Pain of injection

The pain of injection was assessed by the patients with a mean of 2.19 points on the numeric rating scale (NRS) in case of ILA and a mean of 3.65 points in case of IANB

(Table 3; Figure 6). Comparison of the pain of the two anesthetic techniques showed, that the injections were significantly less painful in case of ILA ( $p < 0.001$ ).

	Anesthesia	Injection (n)	Mean	Standard deviation	Standard error of the mean value
<b>Pain of injection (NRS)</b>	ILA	105	2.19	1.79	0.174
	IANB	140	3.65	1.90	0.161

Table 3: Pain of injection related to anesthetic technique

#### 5.1.3.2. Pain during tooth extraction

Immediately after tooth extraction, the pain experienced during the extraction procedure was assessed by the patients with a mean of 1.95 points in case of ILA and a mean of 1.66 points in case of IANB (Table 4 and Figure 6). In accordance, no significant statistical difference was seen ( $p = 0.211$ ).

	Anesthesia	Teeth (n)	Mean	Standard deviation	Standard error of the mean value
<b>Pain during tooth extraction (NRS)</b>	ILA	105	1.95	1.71	0.167
	IANB	140	1.66	1.90	0.161

Table 4: Pain during tooth extraction related to anesthetic technique

#### 5.1.3.3. Unpleasantness of treatment

An assessment with a mean of 2.30 points was given by the patients for tooth extraction under ILA in contrast to a mean of 2.54 points for extraction under IANB (Table 5 and Figure 6). Again, no significant statistical difference was seen ( $p = 0.31$ ).

	Anesthesia	Teeth (n)	Mean	Standard deviation	Standard error of the mean value
<b>Unpleasantness of treatment (NRS)</b>	ILA	105	2.30	1.64	0.160
	IANB	140	2.54	1.96	0.166

Table 5: Unpleasantness of treatment related to anesthetic technique

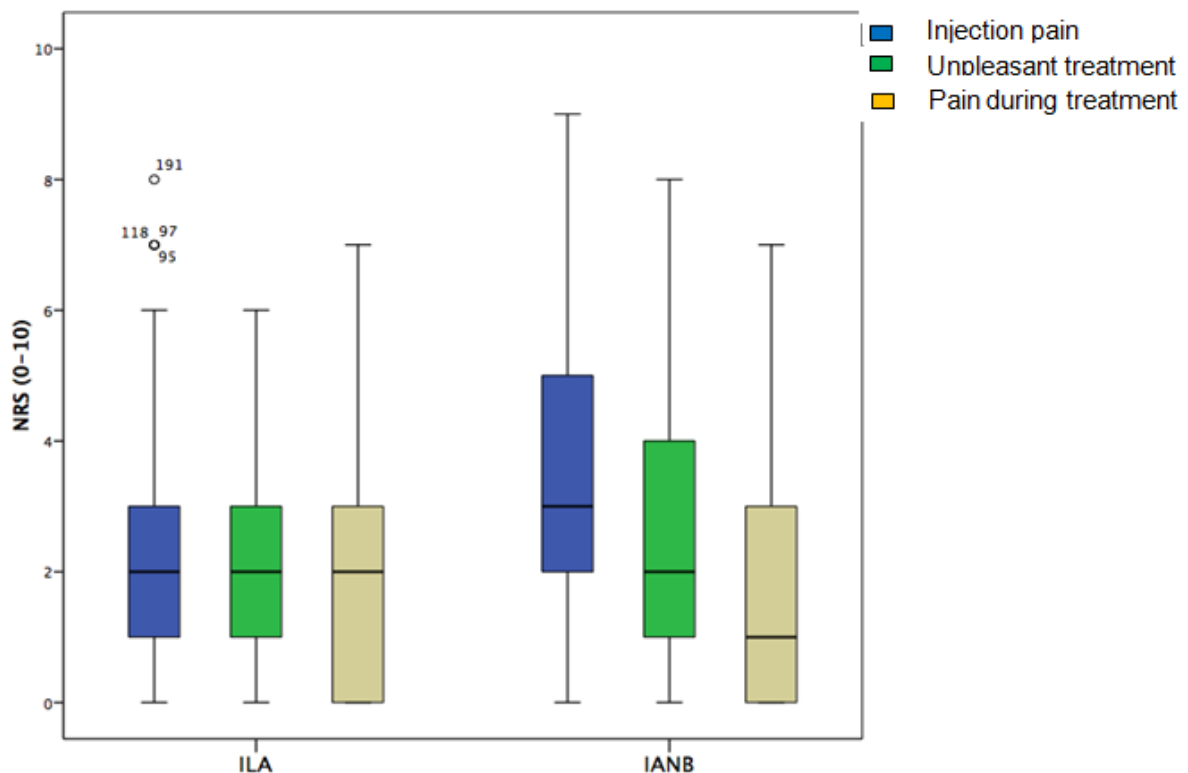


Figure 6: Box plots showing differences in pain of injection, pain during tooth extraction, and unpleasantness of treatment

#### 5.1.3.4. Quality of the anesthetic effect as assessed by patients

The quality of anesthesia was assessed subjectively by the patients using a Likert scale of complete, sufficient, insufficient and no anesthetic effect based on the outcome of the procedure and the patients' experience of pain and discomfort during the course of the treatment. After administration of ILA, complete anesthesia could be achieved in 80 cases (76.19%). In 13 cases (12.38%), the anesthesia was sufficient.

In 11 cases (10.48%), the anesthesia was insufficient and in one case (0.95%), there was no anesthetic effect (Table: 6a).

After IANB, complete anesthesia could be achieved in 109 cases (77.86%). In six cases (4.29%) the anesthesia was assessed as sufficient. In 23 cases (16.42%), anesthesia was insufficient and in two cases (1.43%) there was no anesthetic effect (Table 6a).

		Anesthesia			
		ILA		IANB	
		(n)	(%)	(n)	(%)
<b>Quality of the anesthetic effect</b>	Complete	80	76.19	109	77.86
	Sufficient	13	12.38	6	4.29
	Insufficient	11	10.48	23	16.42
	No effect	1	0.95	2	1.43
<b>Total number of teeth</b>		105	100	140	100

Table 6a: Quality of anesthetic effect assessed by patients

Inability to extract the tooth after the initial injection was considered as primary (initial) anesthesia failure; accordingly, the initial failure rate of anesthesia was 11.43% in case of ILA and 17.85% in case of IANB. When comparing the complete/sufficient effect versus the insufficient/no anesthetic effect of the two techniques of local anesthesia (the proportion of teeth extracted successfully versus the proportion of teeth which could not be successfully extracted after the initial injection), no significant statistical difference could be seen ( $p=0.082$ ; Table 6b).

		Anesthesia			
		ILA		IANB	
		(n)	(%)	(n)	(%)
<b>Quality of the anesthetic effect</b>	Complete/sufficient	93	88.57	115	82.14
	Insufficient/no effect	12	11.43	25	17.86
<b>Total number of teeth</b>		105	100	140	100

Table 6b: Complete/sufficient versus insufficient/no anesthetic effect assessed by patients

Comparing the “complete” versus “sufficient”-ratings assessed by the patients, a statistically significant difference was found in favor for ILA ( $p = 0.03$ ; Table: 6c).

		Anesthesia			
		ILA		IANB	
		(n)	(%)	(n)	(%)
<b>Quality of the anesthetic effect</b>	Complete	80	76.19	109	77.86
	Sufficient	13	12.38	6	4.28
<b>Total number of teeth</b>		93	88.57	115	82.14

Table 6c: Complete versus sufficient anesthetic effect assessed by patients

#### 5.1.3.5. Need for second injection

Second injection of local anesthetic was required in 12 cases (11.43%) of ILA and in 25 cases (17.86%) of IANB (Table 7). Statistically, no significant difference could be found ( $p = 0.197$ ).

		Anesthesia			
		ILA		IANB	
		(n)	(%)	(n)	(%)
<b>Second injection</b>	No	93	88.57	115	82.14
	Yes	12	11.43	25	17.86
<b>Total number of teeth</b>		105	100	140	100

Table 7: Frequency of second injections necessary related to anesthetic technique

The anesthetic technique used for the second injection was always the same technique as for the initial injection. After second injections, complete anesthesia could be attained in 11 cases out of the 12 cases of ILA and in 23 cases of the 25 cases of IANB. In one case of ILA (0.95%) and in two cases of IANB (1.42%), the extraction procedure could not be completed even after second injections. These cases were in the same patients who assessed the anesthesia as “no effect” after initial injection and were categorized as secondary anesthesia failure. In these three cases, a combination of the both anesthetic techniques was used to successfully



extract the teeth. Hence, for the secondary anesthesia failure, there was no significant statistical difference between ILA and IANB ( $p = 0.92$ ).

#### 5.1.4. Parameters of the secondary objectives of this study

##### 5.1.4.1. Amount of local anesthetic solution used at the initial injection

The mean amount of local anesthetic solution used at the initial injections in case of ILA was 0.35 ml, in contrast to a mean of 2.08 ml for IANB (Table 8). Thus, significantly more anesthetic solution was required for IANB ( $p < 0.001$ ).

	Anesthesia	Teeth (n)	Mean	Standard deviation	Standard error of the mean
Amount of anesthetic solution in ml	ILA	105	0.35	0.23	0.022
	IANB	140	2.08	0.27	0.023

Table 8: Amount of the initially used local anesthetic solution related to anesthetic technique

##### 5.1.4.2. Latency time of anesthesia

The time from the injection of the local anesthetic agent to the onset of full anesthetic effect ranged from zero up to one minute in cases of ILA and from one to seven minutes in cases of IANB. The mean latency time for ILA was 0.22 minutes in contrast to 3.32 minutes for IANB (Table 9; Figure 7). The latency time was statistically significantly shorter in cases of ILA ( $p < 0.001$ ). In one case of ILA and two cases of IANB, the latency time could not be determined as the patients reported no anesthetic effect.

	Anesthesia	Teeth (n)	Mean	Standard deviation	Standard error of the mean value
Latency time in minutes	ILA	104	0.22	0.60	0.059
	IANB	138	3.32	1.91	0.161

Table 9: Latency time of anesthesia related to anesthetic technique

### 5.1.4.3. Time between injection and start of extraction procedure

The mean time between injection and start of extraction was 1.10 minutes in cases of ILA, in contrast to a mean of 4.11 minutes in cases of IANB (Table 10; Figure 7). Statistically, tooth extraction could be started significantly earlier after ILA ( $p = 0.001$ ).

	Anesthesia	Teeth (n)	Mean	Standard deviation	Standard error of the mean
Time until start of extraction (min)	ILA	105	1.10	0.96	0.093
	IANB	140	4.11	2.18	0.184

Table 10: Time between injection and start of extraction procedure

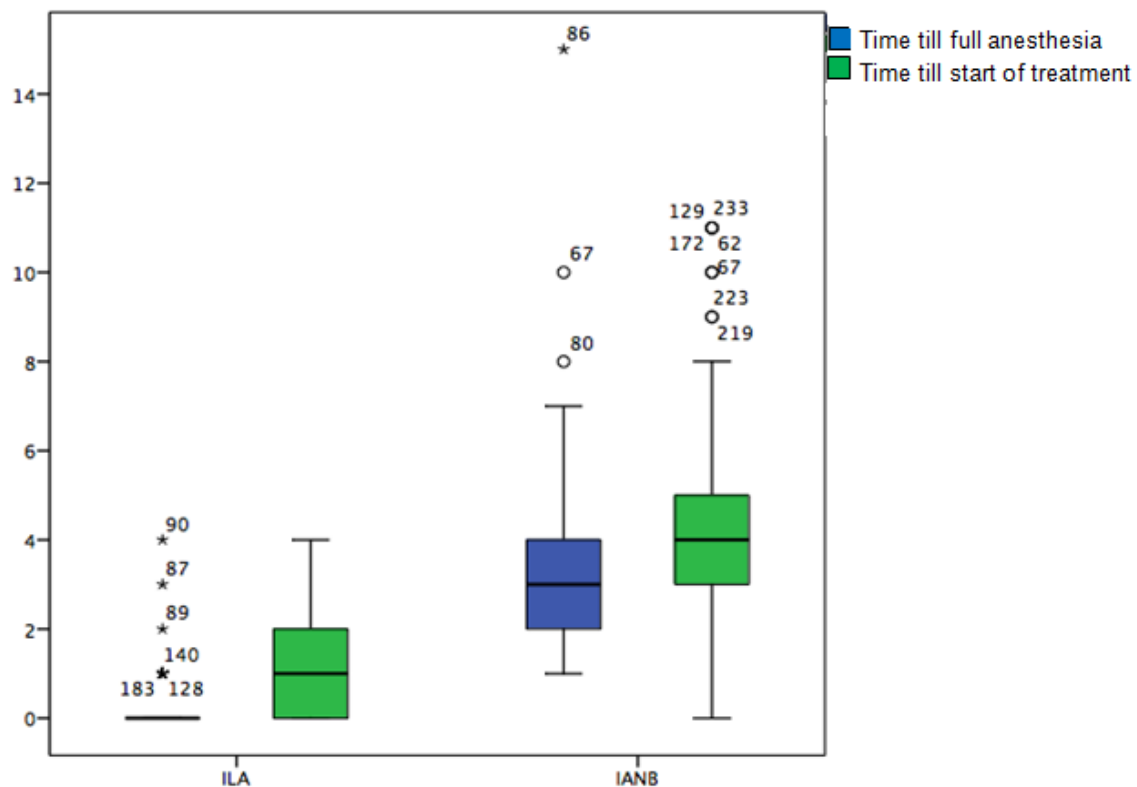


Figure 7: Box plots showing time (min) from injection of local anesthetic to onset of full anesthetic effect and time (min) from injection to start of tooth extraction

#### 5.1.4.4. Time until second injection and amount of anesthetic solution at second injection

The time between the initial injection and the required second injection was statistically significantly longer in case of IANB ( $p < 0.001$ ). As far as the amount of local anesthetic solution for the second injection is concerned, significantly higher amount of local anesthetic was required for the second injection in the case of IANB ( $p < 0.001$ ; Table 11).

	Anesthesia	Teeth (n)	Mean	Standard deviation	Standard error of the mean value
Time until second injection (min)	ILA	12	2.23	1.35	0.407
	IANB	25	7.35	2.44	0.509
Amount of local anesthetic for the second injection (ml)	ILA	12	0.28	0.71	0.213
	IANB	25	1.59	0.48	0.100

Table 11: Time until second injection and amount of local anesthetic for the second injections related to anesthetic technique

#### 5.1.4.5. Duration of entire treatment

In the cases of ILA, the total duration of treatment (time from injection to the end of treatment) ranged from one minute to 27 minutes. On average, the total duration of the treatment was 5.6 minutes. In the cases of IANB, it ranged from four minutes to 36 minutes. On average, the total duration of the treatment in the cases of IANB was 10.7 minutes (Table 12). So, treatment under ILA lasted statistically significantly shorter when compared to IANB ( $p < 0.001$ ). Unfortunately, in two cases of ILA, the duration of treatment was not documented.

	Anesthesia	Teeth (n)	Mean duration	Standard deviation	Standard error of the mean value
Duration of treatment (min)	ILA	103	5.60	5.45	0.537
	IANB	140	10.70	6.94	0.586

Table 12: Duration of treatment related to anesthetic technique

#### 5.1.4.6. Quality of the anesthetic effect as assessed by the dentist

Comparing the quality of anesthetic effect assessed by the dentist, no statistically significant difference could be found between ILA and IANB ( $p=0.15$ ; Table 13a).

		Anesthesia			
		ILA		IANB	
		(n)	(%)	(n)	(%)
<b>Quality of the anesthetic effect</b>	Complete	82	78.09	107	76.43
	Sufficient	11	10.48	8	5.71
	Insufficient	11	10.48	23	16.43
	No effect	1	0.95	2	1.43
<b>Total number of teeth</b>		105	100	140	100

Table 13a: Quality of anesthetic effect assessed by the dentist

Similarly, no statistically significant difference could be determined by comparing the complete/sufficient anesthetic effect versus the insufficient/no anesthetic effect of the two anesthetic techniques ( $p=0.09$ ; Table: 13b).

Comparing the complete against the sufficient anesthetic effect of the two anesthetic techniques also showed no statistically significant difference ( $p=0.051$ ; Table 13c).

		Anesthesia			
		ILA		IANB	
		(n)	(%)	(n)	(%)
<b>Quality of the anesthetic effect</b>	Complete/sufficient	93	88.57	115	82.14
	Insufficient/no effect	12	11.43	25	17.86
<b>Total number of teeth</b>		105	100	140	100

Table 13b: Complete/sufficient versus insufficient/no anesthetic effect assessed by the dentist

		Anesthesia			
		ILA		IANB	
		(n)	(%)	(n)	(%)
<b>Quality of the anesthetic effect</b>	Complete	82	78.09	107	76.43
	Sufficient	11	10.48	8	5.71
<b>Total number of teeth</b>		93	88.57	115	82.14

Table 13c: Complete versus sufficient anesthetic effect assessed by the dentist

#### 5.1.4.7. Duration of soft tissue anesthesia

The duration of soft tissue anesthesia in cases of ILA ranged from 20 minutes up to 80 minutes (average 47.66 minutes). In comparison, for IANB, duration of soft tissue anesthesia ranged from 130 minutes up to 360 minutes (average 228.56 minutes) and was statistically significantly longer ( $p < 0.001$ ; Table 14 and Figure 8).

	Anesthesia	Teeth (n)	Mean	Standard deviation	Standard error of the mean
Duration of soft tissue anesthesia (min)	ILA	104	47.66	33.461	3.265
	IANB	138	228.56	53.382	4.512

Table 14: Duration of soft tissue anesthesia related to anesthetic technique

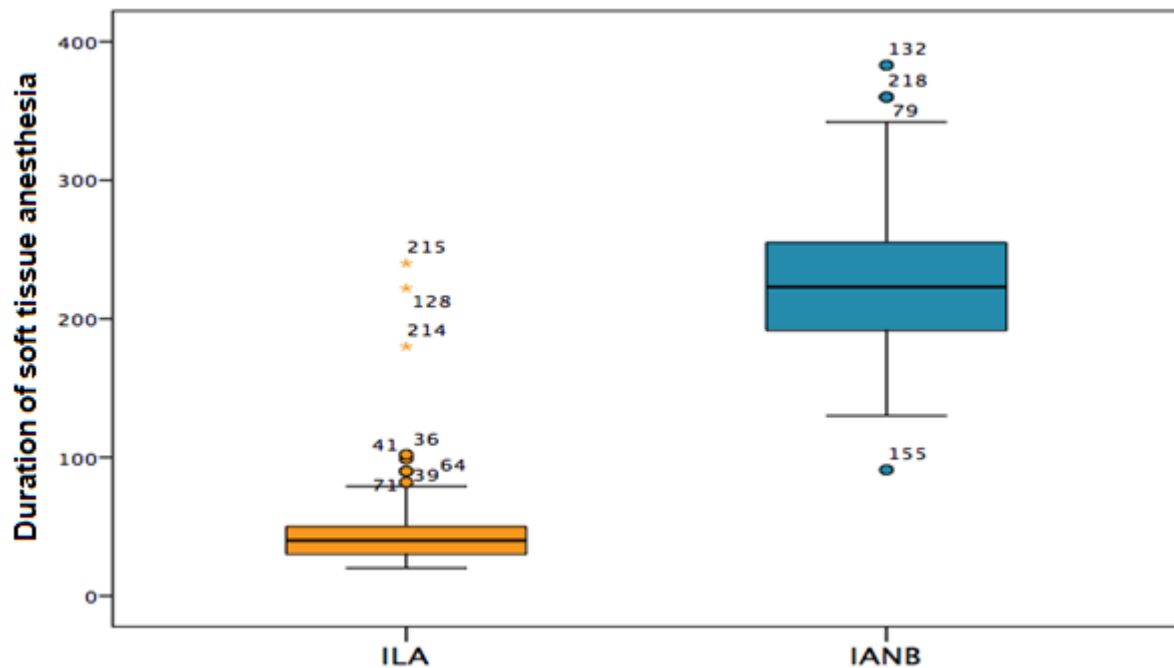


Figure 8: Box plots comparing duration of soft tissue anesthesia (min) in cases of ILA and IANB

#### 5.1.4.8. Frequency of associated complications

No signs of nerve contact were observed in any patient. A positive aspiration was observed in six cases (4.3%) of IANB. Impaired wound healing (dry socket) was observed in six cases (5.7%) after ILA and in three cases (2.1%) after IANB. A comparison of the frequency of occurrence of impaired wound healing after ILA and IANB showed no statistically significant difference ( $p = 0.178$ ). No case of soft tissue necrosis or clinically relevant bacteremia was observed in this study.

### 5.2. Evaluation group II (patients with split- mouth technique)

#### 5.2.1. Patients and teeth

In 28 of the total 266 patients (23 males, 5 females) ILA was administrated on one side of the mandible while IANB was administrated on the other side, as they had teeth to be extracted on both sides of the mandible. Thus, 56 teeth (Table 15) were extracted in these patients (ILA  $n = 28$ , IANB  $n = 28$ ; Figure 9). These 28 patients were a little older than those in the main group (22-87 years, mean 59.2; SD 14.7), were

grown higher (160-186 cm, mean 176.57; SD 6.59) and a little less heavy (45-118 kg, mean 80.8; SD 15.1).

Tooth number	Number of teeth extracted	Percent
<b>34</b>	3	5.36
<b>35</b>	3	5.36
<b>36</b>	9	16.07
<b>37</b>	12	21.23
<b>38</b>	0	0
<b>44</b>	2	3.57
<b>45</b>	4	7.14
<b>46</b>	8	14.29
<b>47</b>	13	23.21
<b>48</b>	2	3.57
<b>Total</b>	<b>56</b>	<b>100</b>

Table 15: Frequency of tooth extractions in group II

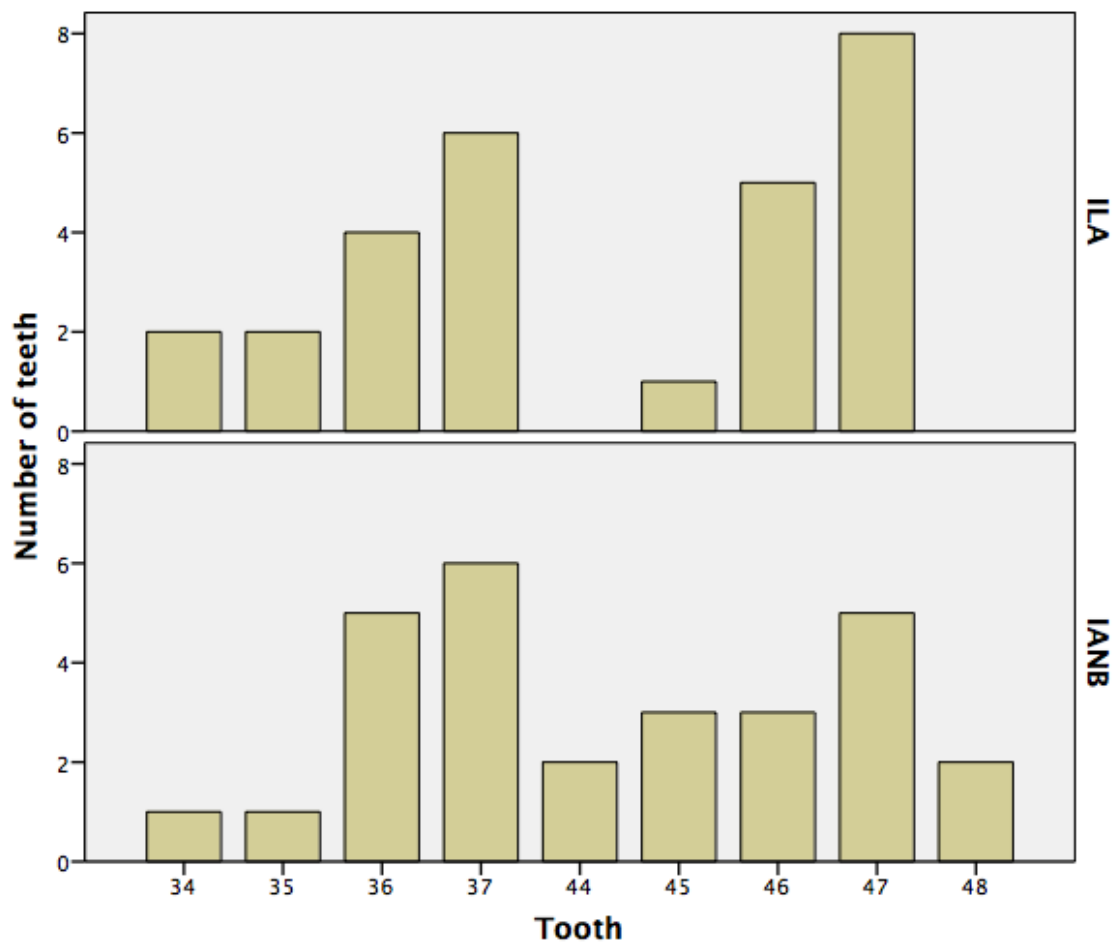


Figure 9: Bar charts showing number of extracted teeth per anesthetic technique in group II

### 5.2.2. Parameters of the primary objectives of this study

#### 5.2.2.1. Pain of injection

The pain of injection was assessed by the patients with a mean of 1.96 points on the NRS in case of ILA and a mean of 4.18 points in case of IANB (Table 16; Figure 10). The comparison of the mean points of the injection pain of the two anesthetic techniques showed, that the injections were statistically significantly less painful in case of ILA ( $p < 0.001$ ).

	Anesthesia	Injection (n)	Mean	Standard deviation	Standard error of the mean value
<b>Pain of injection (NRS)</b>	ILA	28	1.96	1.73	0.327
	IANB	28	4.18	1.79	0.337

Table 16: Pain of injection related to anesthetic technique

#### 5.2.2.2. Pain during tooth extraction

The pain experienced by the patients during tooth extraction was assessed with a mean of 1.64 points in case of ILA and 1.68 points in case of IANB (Table 17; Figure 10). In accordance, no significant difference was seen statistically ( $p = 0.936$ ).

	Anesthesia	Teeth (n)	Mean	Standard deviation	Standard error of the mean value
<b>Pain during tooth extraction (NRS)</b>	ILA	28	1.64	1.39	0.263
	IANB	28	1.68	1.87	0.353

Table 17: Pain during tooth extraction related to anesthetic technique

#### 5.2.2.3. Unpleasantness of treatment

Concerning the unpleasant perception of the entire treatment, an assessment with a mean of 2.14 points was given by the patients for teeth extracted under ILA and 2.50 points for teeth extracted under IANB (Table 18; Figure 10). Comparing the means, no statistically significant difference could be seen ( $p = 0.427$ ).



	Anesthesia	Teeth (n)	Mean	Standard deviation	Standard error of the mean value
<b>Unpleasantness of treatment (NRS)</b>	ILA	28	2.14	1.56	0.294
	IANB	28	2.50	1.77	0.335

Table 18: Unpleasantness of treatment related to anesthetic technique

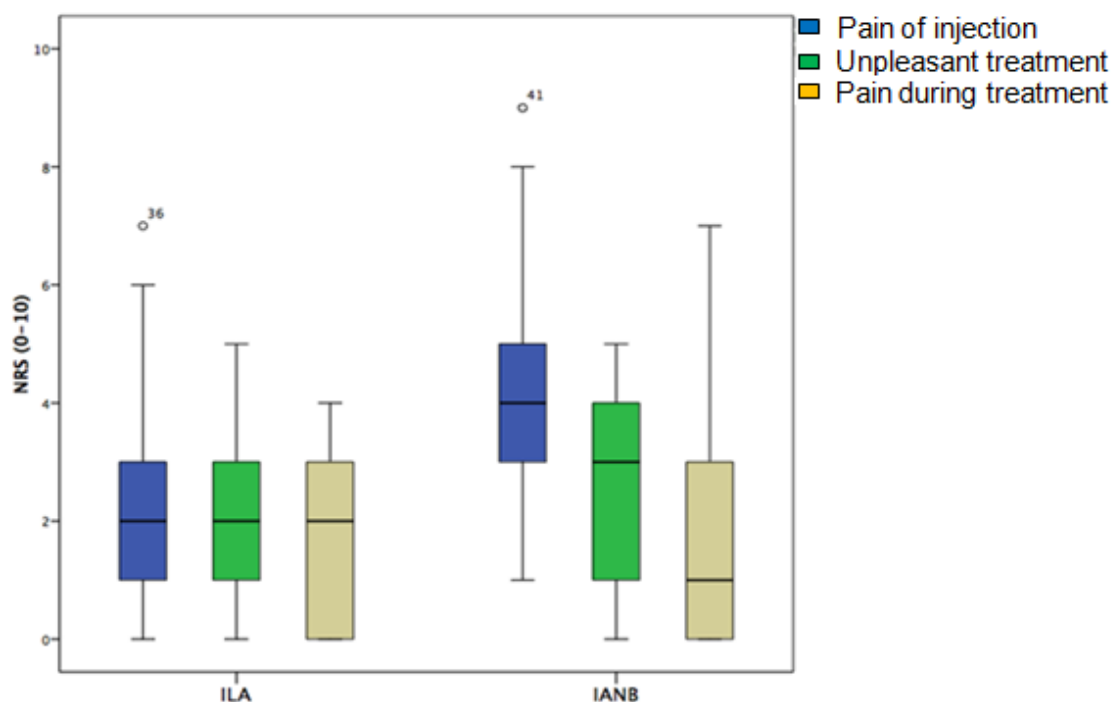


Figure 10: Box plots showing differences in pain of injection, pain during tooth extraction, and unpleasantness of treatment in group II

#### 5.2.2.4. Quality of the anesthetic effect as assessed by patients

After the administration of ILA, complete anesthesia could be achieved in 23 cases (82.14%). In five cases (17.86%), anesthesia was sufficient. After IANB, complete anesthesia could be achieved in 23 cases (82.14%). In two cases (7.14%), the patients assessed anesthesia as sufficient and in three cases (10.72%), the anesthesia was insufficient (Table 19a). Accordingly, the initial failure rate of anesthesia was 10.71% in case of IANB and nil in case of ILA. Though, when

comparing the quality of the anesthetic effect as assessed by patients, no statistically significant difference was seen ( $p= 0.177$ ).

		Anesthesia			
		ILA		IANB	
		(n)	(%)	(n)	(%)
<b>Quality of the anesthetic effect</b>	Complete	23	82.14	23	82.14
	Sufficient	5	17.86	2	7.14
	Insufficient	0	0	3	10.72
<b>Total number of teeth</b>		28	100	28	100

Table 19a: Quality of anesthetic effect assessed by patients

Comparing the complete/sufficient anesthetic versus the insufficient/no effect of the two techniques of local anesthesia (Table 19b), no statistically significant difference could be seen ( $p= 0.236$ ).

		Anesthesia			
		ILA		IANB	
		(n)	(%)	(n)	(%)
<b>Quality of the anesthetic effect</b>	Complete/sufficient	28	100	25	89.29
	Insufficient/no effect	0	0	3	10.71
<b>Total number of teeth</b>		28	100	28	100

Table 19b: Complete/sufficient versus insufficient/no effect assessed by patients

#### 5.2.2.5. Need for second injection

Second injection of local anesthetic was required in three cases of IANB (10.7%). In contrast, no second injection was required in case of ILA (Table 20). Even so, no statistically significant difference could be found ( $p= 0.236$ ).

		Anesthesia			
		ILA		IANB	
		(n)	(%)	(n)	(%)
Second injection	No	28	100	25	89.29
	Yes	0	0	3	10.71
Total number of teeth		28	100	28	100

Table 20: Frequency of second injections necessary related to anesthetic technique

### 5.2.3. Parameters of the secondary objectives of this study

#### 5.2.3.1. Amount of local anesthetic solution used at initial injection and latency time of anesthesia

The mean amount of the local anesthetic solution used at the initial injections in case of ILA was 0.36 ml, in contrast to 2.08 ml in case of IANB (Table 21). For IANB, a statistically significantly higher amount of anesthetic solution was required ( $p < 0.001$ ).

The mean latency time for ILA was 0.32 minutes in contrast to a mean of 4 minutes for IANB (Table 21). Statistically, the latency time was significantly shorter in case of ILA ( $p < 0.001$ ).

	Anesthesia	Teeth (n)	Mean	Standard deviation	Standard error of the mean value
Amount of anesthetic solution (ml)	ILA	28	0.36	0.08	0.015
	IANB	28	2.08	0.23	0.043
Latency time (min)	ILA	28	0.32	0.72	0.137
	IANB	28	4.00	2.82	0.532

Table 21: Amount of initially used local anesthetic solution and latency time of anesthesia

### 5.2.3.2. Time between injection and start of extraction procedure

The mean time between injection of local anesthetic and start of the extraction was one minute in cases of ILA, in contrast to a mean time of 4.11 minutes in cases of IANB (Table 22). Statistically, tooth extraction could be started significantly earlier after ILA ( $p < 0.001$ ).

	Anesthesia	Teeth (n)	Mean	Standard deviation	Standard error of the mean value
Time until start with the extraction (min)	ILA	28	1.00	0.77	0.145
	IANB	28	4.11	2.39	0.452

Table 22: Time between injection and start of extraction procedure

### 5.2.3.3. Duration of entire treatment

On average, the total duration of the treatment from injection to the end of the extraction procedure was 4.81 minutes in case of ILA and 8.64 minutes in case of IANB (Table 23). A comparison of the total duration of treatment under ILA and IANB indicated, that the treatment under ILA lasted statistically significantly shorter than under IANB ( $p = 0.006$ ).

	Anesthesia	Teeth (n)	Mean	Standard deviation	Standard error of the mean
Duration of treatment (min)	ILA	28	4.81	4.25	0.818
	IANB	28	8.64	5.53	1.046

Table 23: Duration of treatment related to anesthetic technique

### 5.2.3.4. Quality of the anesthetic effect as assessed by the dentist

When comparing the quality of anesthetic effect as assessed by the dentist, no statistically significant difference could be found between ILA and IANB ( $p = 0.611$ ). Similarly, no statistically significant difference could be determined when comparing the complete/sufficient versus the insufficient anesthetic effects ( $p = 0.491$ ; Table 24a & b).

		Anesthesia			
		ILA		IANB	
		(n)	(%)	(n)	(%)
<b>Quality of the anesthetic effect</b>	Complete	25	89.28	24	82.14
	Sufficient	3	10.72	1	7.14
	Insufficient	0	0	3	10.72
<b>Total number of teeth</b>		28	100	28	100

Table 24a: Quality of anesthetic effect assessed by the dentist

		Anesthesia			
		ILA		IANB	
		(n)	(%)	(n)	(%)
<b>Quality of the anesthetic effect</b>	Complete/sufficient	28	100	25	89.29
	Insufficient	0	0	3	10.71
<b>Total number of teeth</b>		28	100	28	100

Table 24b: Complete/sufficient versus insufficient effect assessed by the dentist

### 5.2.3.5. Duration of soft tissue anesthesia

On average, the soft tissue anesthesia lasted for 46.07 minutes after ILA in contrast to an average duration of 244.29 minutes after IANB (Table 25). The soft tissue anesthesia lasted statistically significantly longer after IANB ( $p < 0.001$ ).

	Anesthesia	Teeth (n)	Mean	Standard deviation	Standard error of the mean value
Duration of soft tissue anesthesia (min)	ILA	28	46.07	16.39	3.097
	IANB	28	244.29	59.60	11.264

Table 25: Duration of soft tissue anesthesia related to anesthetic technique

### 5.2.3.6. Frequency of associated complications

No signs of nerve contact or a positive aspiration were observed ( $p= 1$ ). Dry socket was observed in only one case of IANB and in none after ILA. Comparison of the frequency of occurrence of impaired wound healing after ILA and IANB revealed no statistically significant difference ( $p= 1$ ; Table 26).

		Anesthesia		Total
		ILA	IANB	
Impaired wound healing	No	28	27	55
	Yes	0	1	1
Total number of teeth		28	28	56

Table 26: Frequency of occurrence of impaired wound healing (dry socket)

## 6. Discussion

In this study, the efficacy of ILA for extraction of mandibular posterior teeth was compared to IANB in a clinical routine setting. The results obtained in this study indicate, that ILA – here using Ultraject® syringe - is at least as efficient as IANB for this indication. In accordance, data showed no statistically significant differences between the success rates and the profoundness of local anesthesia obtained with the two anesthetic techniques. In certain aspects, ILA is found to be even superior to IANB. Hence, ILA was significantly less painful to the patients, had a significantly shorter latency time, enabled a shorter duration of treatment and required a significantly smaller amount of local anesthetic solution in comparison to IANB. The results show furthermore, that ILA - properly applied – can be used as a primary anesthetic technique unrestricted for almost all nonsurgical extractions of mandibular posterior teeth.

This study was a prospective, randomized, comparative clinical trial with a sample size comparable to - if not more than - that of similar studies [Heizmann and Gabka, 1994; Dumbrigue et al., 1997]. Heizmann and Gabka [1994] compared ILA administered with Citoject® syringe (teeth= 110/ maxillary= 56; mandibular= 54) against IANB (teeth= 110/ maxillary= 0; mandibular= 110) and infiltration anesthesia (teeth= 110/ maxillary= 76; mandibular= 34) in extraction of maxillary and mandibular teeth on a total of 255 patients (ILA= 83; IANB= 85; infiltration= 87). Dumbrigue et al. [1997] compared ILA (teeth= 24) administered using a pressure syringe (Ligmaject®) against IANB (teeth= 21) administered using conventional aspirating syringes on 16 patients requiring bilateral mandibular dental extraction (split-mouth).

In this present study, ILA administered with Ultraject® syringe (teeth n=133) was compared to IANB administered with conventional disposable injection syringes (teeth n= 168) for extraction of mandibular posterior teeth on a total of 266 patients (ILA= 126; IANB= 168). These 266 patients were categorized into two evaluation groups (evaluation group I and II) based on whether only one or both anesthetic techniques were used in individual patients (unilateral or bilateral tooth extraction). 238 patients with unilateral mandibular dental extractions who received randomized either ILA or IANB as anesthetic technique were included in evaluation group I. Evaluation group II (split-mouth) consisted of 28 patients with bilateral mandibular dental extractions who received both ILA and IANB, each on one side of the mandible. ILA was compared with IANB in each evaluation group and the results in

the two groups were compared to each other. In group I, a total of 245 teeth were extracted (ILA= 105; IANB= 140) from a total of 238 patients (ILA= 98; IANB= 140) whereas in group II, a total of 56 teeth (ILA= 28; IANB= 28) was extracted from 28 patients.

The general patients' parameters (number, age, height, and body weight, medical and dental histories) of the patients anesthetized with ILA and those anesthetized with IANB were relatively similar and showed no statistically significant differences. The patients in evaluation group II were a little older, were grown higher and a little less heavy than those in evaluation group I.

All of the injections, teeth extractions, and data collection in this study were performed by only one dentist allowing the influence of the dentists' variables to be minimized. As mentioned above, in evaluation group II (28 patients, 56 teeth), the study was designed as a split-mouth technique. Here, instead of having different patients for each anesthetic technique, the same patients received first ILA and then IANB. Hence, the influence of the patients' variables on the results could be minimized as well. The study data of this group of patients were evaluated separately and the results were found to be in a high coincidence with those of the evaluation group I.

The Ultraject® syringes used in this study for the administration of ILA are equipped with a built-in safety pressure control mechanism; so that, independently of the individual injection behavior, the injection of local anesthetics always takes place patient-friendly, thereby reducing the unwanted effects. Ultraject® syringes have a pressure limitation of 120 N. Converted to the surface area on which the pressure is applied (the inner diameter of 0.3 mm needle), this results in a final injection pressure of about 3.2 MPa [Zugal et al. 2005].

Concerning the general medical conditions of the patients, only a small proportion of the entire study sample showed co-morbidities. Therefore, it may be assumed that there was no statistically significant influence of the general medical history on the results or on the effects of anesthesia. The same applies to the history of regular intake of medication. In the entire study sample, only three patients reported acute dental pain before treatment. Therefore, a statement about the correlation between the pain prior to treatment and the failure of the anesthesia can – unfortunately -



neither be excluded nor confirmed. Von Haussen [2011] claimed a positive correlation between preoperative pain and failure of ILA. He reported about failure of ILA - administered with STA<sup>TM</sup>-system - in five from a total of eight patients who had reported about pain preoperatively. The influence of pain medication on the results can be ruled out since patients who have taken a pain medication before treatment were excluded from this study.

The pain perceived by patients during the different steps of treatment is an important aspect in the evaluation of the efficacy of anesthetic techniques. In accordance, an objective method of pain measurement should be employed. Though, the basic problem is that pain is a personal subjective experience and cannot be visualized or felt by another person in the same way. So, only indirect methods – such as physiological, behavioral and report by the patient - can be used for this purpose. In this study, a numeric rating scale (NRS) consisting of 11 points (0= no pain; 10 extreme pain) was used. The patient selected a number from 0 to 10 that best reflected the intensity of pain he/she felt. Although this method can be affected by fear and expectation of pain by the patient, it is the most reliable and commonly used method [Ardakani et al., 2010].

Regarding the pain of injection, a statistically significant difference between ILA and IANB was found in this study. The injections in cases of ILA were significantly less painful to the patients than that in cases of IANB ( $p < 0.001$ ). In both evaluation groups, the injection of ILA was rated with significantly fewer points on the NRS (2.2 points in group I; two in group II) than that of IANB (3.7 points in group I; 4.2 in group II). However, the injection pain in evaluation group II was rated to be relatively less in cases of ILA compared to IANB. In other words, the injections of IANB seemed to be more painful than ILA in group II when compared to group I. In group II, ILA was administered first on one side, and then IANB was administered in the same appointment on the other side of the mandible. This could potentially affect the patients' perception of pain during subsequent injections and may explain why the injection pain of IANB was rated worse. This result is in accordance with that in many other previous studies. Einwag [1982] reported an absence of pain response for ILA injection. Heizmann and Gabka [1994] reported about injection pain in 7.2% of 110 cases of tooth extraction under ILA and in 10% of 110 cases under IANB. Zugal [2001] noticed injection pain in 27 (13.2%) from 205 cases of ILA, while Weber [2005]

reported injection pain in two (1.5%) of 137 cases of ILA and in 35 (26.9%) of 130 cases of IANB. In these four studies mentioned above, the evaluation was based on the patients' report about injection pain with yes/no answers. Kaufman et al. [2005] reported injection pain with a mean of 2.74 points in 45 cases of ILA and a mean of 3.54 points in 61 cases of IANB. Prama et al. [2013] reported injection pain with a mean of 1.7 points in 20 cases of ILA and a mean of 3.4 points in 20 cases of IANB, while Kämmerer et al. [2015] reported on injection pain with a mean of 1.55 points in 22 cases of ILA and a mean of 3.05 points in 20 cases of IANB. In the last three studies mentioned above, a numeric rating scale from 0-10 was used for evaluation of injection pain.

However, not all authors came to the same conclusions. Dumbrigue et al. [1997] found that the injections of ILA were associated with more pain and discomfort to the patient than that of IANB. Moreover, the authors concluded, that the profoundness of local anesthesia was less after ILA. However, it must be noticed that Dumbrigue – in the statistical analyses of the injection pain - has not taken each extracted tooth as an independent sample, but considered the total number of patients. As in some patients, more than one tooth was extracted under ILA, multiple intraligamental injections were required in the same quadrant. This may account for the observed greater patients' discomfort during injections associated with ILA. Furthermore, Dumbrigue has used Ligmaject® syringe for the administration of ILA. When such pistol type syringes without safety pressure limiting mechanism are used, the injection takes place rapidly under higher pressure than required and the injection pain increases obviously [Walton and Abbott, 1981; Giovannitti and Nique, 1983]. In addition, the sample size in the study of Dumbrigue et al. was small (16 patients, 45 teeth). Hence, the results of such studies, with small study sample should not be taken without caution and reservation.

It must also be recognized, that there several other procedural factors possibly associated with pain experience during the injection of local anesthetic such as type of anesthetic solution, amount of injected solution, temperature of the anesthetic solution, injection rate, location of injection and experience of the dentist [Arjen et al., 2009].

Regarding the amount of local anesthetic solution required, a statistically significant difference was found between ILA and IANB both in group I and II ( $p < 0.001$ ). The

mean amount of local anesthetic solution used at initial injections in both evaluation groups was similar in case of ILA (0.4 ml) and similar in case of IANB as well (2.1 ml). In each group, a significantly higher amount of local anesthetic solution was required for IANB, both at initial and second injections. This fact is technique immanent and, of course, coincides with that used by many other Authors. Stoll and Bührmann [1983] used a mean amount of 0.3-0.4 ml of local anesthetic in 57 cases of ILA. Heizmann and Gabka [1994] used a mean of 0.3 ml for ILA and 2.4 ml for IANB, while Dirnbacher [2003] injected a mean amount of 0.4 ml for ILA and 1.8 ml for IANB. By Weber [2005], a mean of 0.47 ml for ILA and 1.9 ml for IANB were required. Dombrigue et al. [1997] injected a mean of 0.2-0.4 ml anesthetic for ILA and 1.9 ml for IANB. However, Rahn et al. [1987] used a mean of 0.8 ml of local anesthetic for ILA and was able to reach only 60% success rate in 47 cases.

The latency time of anesthesia was determined through testing the anesthetic effect on the gingiva at regular time intervals using a sharp dental probe. ILA – technique immanent – has virtually no latency. However, according to the observation by the dentist in this study, a latency of 30 seconds up to one minute must be expected in inflamed tissues. In this study, ILA was found to have a statistically significant shorter latency time than IANB ( $p < 0.001$ ). The mean latency time after ILA was 0.22 minute in group I and 0.32 minute in group II. In case of IANB, mean latency times of 3.32 minutes and four minutes were determined in group I and II, respectively. This result corresponds to that in many previous studies. A practically no latency after ILA was reported by many authors [Gray et al., 1987; Cohen et al., 1993; Heizmann and Gabka, 1994; Zugal et al., 2005; Weber et al., 2006]. After IANB, mean latency times of three minutes and 3.80 minutes were reported by Heizmann & Gabka [1994] and by Dirnbacher et. al. [2003], respectively. For Weber [2005], this value was 4.6 minutes.

Of course, electric pulp testing would have given more objective fundamental information in regard of the pulp anesthesia. Therefore, the used methods for subjective evaluation of gingival anesthesia should be considered to be a possible bias of this study.

Being able to begin with the extraction procedure immediately after the injection of the local anesthetic, ILA does offer the advantages of saving time, reducing the treatment time and the duration of patients' stay on the dental chair, which in turn

reduces the psychological distress of the patients. Furthermore, by eliminating the need of bridging the long latency time by changing the room and working at other patients ("room-hopping"), the patient stays under continuous observation by the dentist after the injection and actions can be taken immediately in case of eventual complications.

In relation to the total duration of treatment, measured from the time of injection until the end of the extraction procedure, a significant difference was found between ILA and IANB. The mean duration of treatment in group I was 5.6 minutes after ILA and 10.7 minutes after IANB. In group II, these values were 4.8 and 8.6 minutes after ILA and IANB, respectively. In both evaluation groups, the duration of treatment was significantly longer in the cases of IANB ( $p < 0.001$ ; 0.006 in group II). This was especially due to the longer latency time of anesthesia after IANB.

With an average treatment time of 10.70 minutes and an average latency time of 3.32 minutes, 31% of the total treatment time was required for waiting for the anesthetic effect of IANB. Only in the remaining 69% of the time, extraction procedures took place. Measured from the beginning to the end of the extraction procedure, Heizmann and Gabka [1994] reported a mean treatment time of 3.5 minutes after ILA and 6.4 minutes after IANB. The mean times measured from the beginning to the end of extraction procedures obtained in this present study – after subtracting the mean latency times – were 5.4 and 7.4 minutes for ILA and IANB, respectively (4.5 and 4.6 minutes in group II). These mean times of treatment are a little bit longer but comparable to that obtained by Heizmann and Gabka [1994].

Since the treatments in all cases of ILA and IANB had always been completed while the maximal effect of anesthesia was still present, it is unlikely that the differences in the duration of treatment could have had effects on the results, in particular, the quality of anesthesia.

In regard to the pain experienced by the patients during the extraction procedures, no statistically significant difference between ILA and the IANB could be found in this study ( $p = 0.211$ ; 0.936 in group II). Similarly, no significant difference could be found regarding the unpleasantness of the entire treatment under ILA and IANB ( $p = 0.31$ ; 0.427 in group II).

In this present study, a success of local anesthesia was judged when teeth can be extracted without or with mild but tolerable pain and discomfort. In group I, an initial success rate of 88.6% in case of ILA (99% after second injections) and 82.14% in case of IANB (98.6% after second injections) could be achieved. The initial success rate in group II was 100% for ILA and 89.3 (100% after second injections) for IANB. The difference in success rate of ILA and IANB after the first injections was statistically not significant ( $p= 0.082$ ;  $0.236$  in group II). Similarly, no statistically significant difference between the success rates of ILA and IANB could be found after second injections both in group I and II ( $p= 0.92$ , one respectively).

The initial success rates of ILA and IANB achieved in this study are comparable to that reported by others. Heizmann [1989] could achieve an initial success rate of 86.4% with ILA (99.1% after second injections) and 84.5% with IANB (100% after second injections) in extraction of 110 maxillary and mandibular teeth. Considering the only extraction of mandibular teeth, the success rate achieved by Heizmann was 81.5% in extraction of 54 teeth with ILA and 84.5 in extraction of 110 teeth with IANB. However, not all authors came to the same result. Some authors could achieve a higher success rate with ILA in dental extraction [Faulkner, 1983; Kaufman et al., 1983]; and others achieved a lower success rate than that in this present study [Edward and Head, 1989; Dombrigue et al., 1997]. Faulkner [1983] could achieve 97% success rate in extraction of 100 teeth. Kaufman et al. [1983] reported a 95% success rate in a total of 22 cases. In the preceding studies [Faulkner, 1983; Kaufman et al., 1983], success was defined as completion of the extraction procedures without any discomfort. All cases in which additional anesthesia was required or in which the procedure could not be completed at that visit were considered as failures.

Edwards and Head [1989] reported a 79% success rate of ILA in extraction of 14 teeth. Dombrigue et al. [1997] reported about success rate of 75% in extraction of 24 mandibular posterior teeth with ILA and 95% in extraction of 21 mandibular posterior teeth with IANB. Second injections were required in 12 cases (50%) of ILA and in one case (4.8%) of IANB.

In this present study, in addition to the evaluation by the patients, the success of the anesthesia was also evaluated by the dentist based on his 12 years long experience in dental extraction under local anesthesia and served as a control of the patients' evaluation of success to minimize the bias that might be caused by overestimation by

the patients. The evaluations of anesthetic success made by the patients are found to coincide in the greatest part with that indicated by the patients.

Another point of discussion is related to the total duration of soft tissue anesthesia. The duration of soft tissue anesthesia after IANB is – technique immanent – significantly longer than that after ILA. In accordance, the results of this study showed that the total duration of marginal soft tissue anesthesia was statistically significantly longer after IANB than after ILA ( $p < 0.001$ ). The average duration of ILA was 47.7 minutes in group I and 46 minutes in group II whereas the average duration of IANB was 228.6 minutes; 244 minutes in group II.

The average duration of ILA obtained in this study is higher than that obtained by some authors such as 30 minutes [Heizmann, 1989; Dirnbacher, 2002; 2003; and Endo et al., 2008] and 31.8 minutes [Weber, 2005]; but lower than that obtained by some others such as 56 minutes [Cisides, 2009], 74.1 minutes [Langbein, 2011] and 61 minutes [Kämmerer et al., 2014]. The duration of IANB obtained in this study is comparable to that reported in the literature [Heizmann and Gabka, 1994; Dirnbacher, 2002, 2003; Weber, 2005; Endo et al., 2008; Cisides, 2009; Kämmerer et al., 2014]. These authors reported that the soft tissue anesthesia lasted for more than 200 minutes after IANB.

This duration of soft tissue anesthesia after IANB may be considered to be unnecessarily long and without reasonable ratio to the treatment time. In accordance, for IANB, the average duration of treatment was 10.7 minutes whereas the average duration of soft tissue anesthesia was 228.6 minutes. This means, that only 4.7% of the total duration of anesthesia was used for the actual treatment. In consequence, the patients remained limited in their dispositions for hours after the end of treatment. In those cases, functions of mastication and speech are usually disrupted and the risk of bite or thermal injury, especially in children and in patients with mental disabilities, is increased.

No signs of nerve injury were noticed in this study after IANB. According to the literature, a persistent or even permanent nerve involvement after IANB may occur in one from 20,000-850,000 cases [Pogrel, 2007]. Consequently, a direct comparison of this result with that obtained in this study is difficult due to the small sample size.

A positive aspiration was observed in six cases (8.4%) of IANB. This frequency of positive aspiration is comparable to that of 8.2% reported by Persson et al. [1974] but differs from that reported by other authors such as 11.7% [Bartlett, 1972], 11% [Rood, 1972], 30% [Evers and Haegerstam, 2000] and 4.3% [Vasconcelos et.al., 2008]. With ILA, positive aspiration or a contact with a large blood vessel can virtually be excluded.

Expected was an increase in the frequency of occurrence of dry socket after ILA as the local anesthetic solution with its vasoconstrictor content is injected in the direct vicinity of the extraction site, which could impair the building of blood coagulum necessary for the wound healing. In addition, adrenaline and other vasoactive agents possess fibrinolytic activity [Mannucci et al., 1985]. In the entire study sample of this study, however, impaired wound healing (dry socket) was observed in six cases (4.5%) after ILA and in four cases (2.4%) after IANB. In accordance, there was no significant difference between ILA and IANB in regard to the frequency of occurrence of dry socket ( $p= 0.178$ ; one in group II). This result coincides with others [Tsirlis et al., 1992; Heizmann and Gabka, 1994]. Tsirlis et al. [1992] observed dry socket in six cases (4.3%) after 139 dental extractions with ILA and in five cases (3%) after 166 extractions with IANB using 2% lidocaine with 1:80.000 epinephrine as a local anesthetic in all cases. Heizmann and Gabka [1994] reported on six cases of dry socket (5.5%) after extraction of 110 teeth with ILA and on five cases (4.5%) after extraction of other 110 teeth with IANB using 4% articaine with 1:200,000 adrenaline as a local anesthetic for both anesthetic techniques. In this present study, 4% articaine with 1:200.000 adrenaline was the local anesthetic used for both anesthetic techniques as well. Whether the choice of local anesthetic agents and the different concentrations of vasoconstrictor in local anesthetic agents might influence the incidence of dry socket after ILA, remains a subject of debate in the literature. Meechan et al. [1987] claimed that the choice of local anesthetic agents could have an influence on the frequency of occurrence of dry socket. He observed a significant increase in the frequency of occurrence of dry socket after using Xylocaine (2% lignocaine with 1:80.000 adrenaline) as compared to Citanest (3% Prilocaine with 0.03 IU/ml felypressin). He concluded that this difference in the incidence of dry socket was due to the difference in the haemostatic ability of the two vasoconstrictors. Meyer [1971] considered the influence of the vasoconstrictor to be

important. However, Nitzan [1983] could not find a significant difference in the incidence of dry socket after teeth extractions under local and general anesthesia; he concluded that vasoconstrictor can have no effect on the production of dry socket. Birn [1973] stated that any vasoconstrictor effect on the incidence of dry socket is unproven.

Testing the possible influences of different adrenaline concentrations in local anesthetic agents on the efficacy of ILA for dental extraction and on the possibly associated complications is the subject of our research in the future. We assumed that the amounts of adrenaline administered during ILA are very small and do not contribute considerably to the production of dry socket.

Even if it was not an objective of this study, no signs or symptoms of manifested bacteremia were observed in this study. Rahn et al. [1986] noticed a significant increase in the incidence of bacteremia after ILA and advised the use of conventional anesthesia by patients with increased risk of endocarditis. In our opinion, the risk of bacteremia during intraligamental injection is not considerably higher than that during other dental treatment measures. In patients prone to endocarditis, in accordance to the German guidelines, antibiotic prophylaxis is carried out anyway.

Since a large proportion of the data analyzed in this study was obtained from the patients' own answers of questions concerning the study parameters, the data are not completely objective and may reflect individual, personal assessments. Pain threshold and its tolerance may vary in individual patients; and the perception of pain can be modified by psychological, social and situational factors. For this reason, it must be recognized that there are inherent limitations in conclusions that may be drawn from a study thus designed.



## 7. Conclusion

Based on the results of this study, the following conclusions can be derived:

ILA represents a safe and reliable method of local anesthesia with a success rate comparable to that of the conventional inferior alveolar nerve block for mandibular dental extraction. So, it can be considered as a reliable alternative to IANB. Moreover, it does offer several advantages for the patient and dentist over the conventional IANB.

The injection of ILA is significantly less painful to the patients than the conventional nerve block anesthesia making it a preferable method of anesthesia especially for children and patients with fear and anxiety.

ILA has virtually no latency, so that it is possible to evaluate the anesthetic effect and to start with treatment immediately after the injection of the local anesthetic solution. Being able to begin with treatment immediately after the injection, ILA does offer the advantages of saving time, reducing the total treatment time and the duration of patients' stay on the dental chair, which in turn reduces the psychological distress of the patients.

For ILA, only a small amount of local anesthetic solution is required. In consequence, the risk of overdosing and systemic reactions due to local anesthetics' toxicity is lower than that after IANB. This risk should be considered, especially in children and in patients with cardiovascular diseases as well as when treating many teeth in different quadrants in the same appointment.

ILA enables a shorter duration of anesthesia in comparison to the nerve block anesthesia. This duration is usually enough to complete the majority of dental treatments. At the same time, the patient can resume his normal activity shortly after the completion of treatment. Additionally, the local anesthetic effect is limited to the region of the tooth to be treated without concomitant anesthesia of the lip and tongue. The speech and chewing functions are minimally affected and the risk of postoperative bite and burn injuries decreases.

The risk of injury to the blood vessels and hematoma formation with ILA can practically be excluded. With the increasing proportion of elderly patients and patients with cardiovascular diseases taking anticoagulants, the number of risk patients in the daily dental practice increases. ILA should be considered as the anesthetic method of choice for these patients.

With ILA, there is practically no risk of nerve injury. Considering the actual jurisprudences, the patients must be informed about the risks and complications of an indicated health measure and about the alternative therapy measure. So, ILA must be offered as an alternative to the nerve block anesthesia. In recent judicial procedures about injuries to the inferior alveolar nerve, the attending dentists were condemned because they had not offered ILA as a possible alternative and had not given the patient the possibility of choosing another method of anesthesia.

Taking into account the potential complications of the inferior alveolar nerve block, ILA should be considered as a preferred anesthetic technique especially for single tooth treatment while IANB should be limited only to cases in which ILA failed to provide the sufficient anesthesia and in cases of dentoalveolar surgical procedures requiring a longer time or for treating many teeth in the same quadrant.

## 8. Summary

Usually, the nature of the bone of the adult posterior mandible requires the use of regional nerve block to obtain anesthesia for most dental procedures. Inferior alveolar nerve block (IANB) is considered as a reliable technique of local anesthesia and is still the most commonly used technique in the lower jaw, especially when treating many teeth in the same quadrant. However, IANB has a relatively high failure rate and technique immanent risk of complications, such as transient or even persistent damage of the lingual and/or the inferior alveolar nerve. In consequence, the need for an alternative anesthetic technique with higher success rate and lower risk of complications is increased. Intraligamentary anesthesia (ILA) is considered to be an efficient and clinically safe technique of local anesthesia and appears to be an interesting alternative. For ILA, the local anesthetic solution is injected directly into the periodontal ligament space of the tooth to be treated and shows its effect only in this region. So far, there is a lack of respective studies on this topic.

The purpose of this prospective, randomized clinical trial was to test whether ILA applied using a pistol-type syringe with a built-in pressure limiting mechanism (Ultraject®) can be considered as a valid alternative to – or offers advantages for the patients over - the conventional IANB in extraction of mandibular posterior teeth.

266 adult patients of both sexes (176 males, 90 females) with one or more mandibular posterior teeth indicated for extraction were included in this study. 301 extractions of mandibular posterior teeth (ILA= 133 teeth, IANB= 168 teeth) were evaluated. Patients were categorized randomly into those who received ILA and those who received IANB as a local anesthetic technique for the indicated dental extraction. When bilateral mandibular dental extractions were indicated, ILA was randomly used first on one side and then IANB on the other. All injections, teeth extractions, and data collection were carried out by one and the same dentist. The anamnestic patient data, as well as the descriptive study data were collected using especially designed evaluation sheet. The study parameters were assessed using Likert scale or numeric rating scale.

After treatment and before statistical data evaluation, the patients were further categorized into two evaluation groups based on whether only one anesthetic technique (unilateral) or both techniques (bilateral) were used in the individual patients. In evaluation group I were patients (patient n= 238, teeth n= 245) with

unilateral dental extraction who received either ILA (teeth n= 105) or IANB (teeth n= 140), while in evaluation group II (split-mouth) were patients with indicated bilateral dental extraction (patient n= 28, teeth n= 56) and who received both ILA (teeth n= 28) and IANB (teeth n = 28), each in one side of the mandible. ILA was compared with IANB within each evaluation group and the results of the two groups were then compared with each other.

The two techniques of dental local anesthesia were compared with the help of several parameters (pain of injection, pain during tooth extraction, anesthetic quality, need for second injection, amount of anesthetic solution required, duration of anesthesia, and frequency of complications). The primary objectives were to evaluate the difference in pain perceived by the patient during treatment as well as the anesthetic efficacy (complete/sufficient vs. insufficient/no effect) based on the outcome of treatment and the degree of discomfort associated with the extraction procedure. Of secondary interest were the amount of local anesthetic solution required, the duration of treatment, the duration of soft tissue anesthesia, and the frequency of complications. Each extracted tooth was considered as an independent sample.

The collected data were tabulated and analysed statistically. A global significance level was chosen to 0.05. For explorative data analysis, Kolmogorov-Smirnov test was employed to test for a difference between the two anesthetic techniques. In cases of p-values <0.05, Mann-Whitney-U test and in cases of p-values >0.05, Students' t-test for independent samples were employed.

The results in evaluation groups I and II were found to coincide in the greatest part with each other. The injection of ILA was statistically significantly less painful for the patients in both evaluation groups ( $p < 0.001$ ). In evaluation group II, IANB was statistically much more painful for the patients than ILA in comparison to that in group I. In group II, ILA was administered first on one side, and then IANB was administered in the same appointment on the other side of the mandible. This could potentially affect the patients' perception of pain during subsequent injections and may explain why the injection pain of IANB was rated worse. The difference in pain experienced by the patients during tooth extraction under ILA and IANB was statistically not significant ( $p = 0.211$ ;  $0.936$  in group II). Similarly, no statistically significant difference could be found when comparing the unpleasantness of treatment ( $p = 0.31$ ;  $0.427$  in group II).

The success rate of ILA in extraction of mandibular posterior teeth was 88.6% after just one injection (100% in group II); this rate increased to 99% after second injection. IANB, however, had a success rate of 82.2% after first injection (89.3% in group II), and 98.6% after second injection (100% in group II). The difference between the success rates of ILA and IANB was statistically not significant ( $p= 0.082$ ;  $0.236$  in group II).

The latency between the injection of the local anesthetic and the onset of the full anesthetic effect was significant shorter after ILA ( $p< 0.001$ ); thus, it was possible to start with the extraction immediately after the injection, shortening the total time required for the treatment and saving time. In addition, the amount of local anesthetic solution used was substantially less in cases of ILA when compared with IANB ( $p< 0.001$ ).

The duration of soft tissue anesthesia after IANB was significantly longer than that after the ILA ( $p< 0.001$ ) and exceeded by far the time required for the extraction. Regarding the frequency of associated complications, no case of nerve injury was observed. Positive aspiration was observed in six cases (4.3%) of IANB in group I and in nil case in group II. In the entire study sample (group I and II), dry socket was observed in six cases (4.5%) after ILA and in four cases (2.4%) after IANB. In accordance, there was no significant difference between ILA and IANB in regard to the frequency of occurrence of dry socket ( $p= 0.178$ ; one in group II).

Based on the results of this present study, it can be concluded that ILA represents a safe and reliable alternative to the conventional IANB in extraction of mandibular posterior teeth. Taking into account the potential complications of the inferior alveolar nerve block, ILA should especially be considered as a preferred anesthetic technique for single tooth treatment while IANB should be limited only to cases in which ILA failed to provide the sufficient anesthesia and in cases of dentoalveolar surgical procedures requiring a longer time or for treating many teeth in the same quadrant.

## 9. References

- Adubae A, Buttchereit I, Kämmerer PW (2016). Extraktion unter ILA bei einer Phobie-Patientin. Zahnärztl Mitt 106(5):42-45
- Anand P, Wilson R, Sheehy EC (2005). Intraligamental analgesia for post-operative pain control in children having dental extractions under general anaesthesia. Eur J Paediatr Dent 6:10-15.
- Anneroth G, Danielsson KH, Evers H, Hedström KG, Nordenram A (1985). Periodontal ligament injection. An experimental study in the monkey. Int Oral Surg 14:538-543.
- Ardakani FE, Bahrololoumi Z, Booshehri MZ, Azam AN, Ayatollahi F (2010). The position of lingual as an index for inferior alveolar nerve block injection in 7-11 year-old children. JODDD 4:47-51.
- Bartlett SZ (1972). Clinical observations on the effects of injections of local anesthetic preceded by aspiration. Oral Surg Oral Med Oral Pathol 33:520-526.
- Bender W, Taubenheim L (2014). Minimalinvasive Lokalanästhesie- keine Aufklärungspflicht. ZWP online- Das Nachrichtenportal für die Dentalbranche.
- Bendquide V, Akkareddy B, Jawale BA, Chaudhary S (2011). An unusual pattern of self-inflicted injury after dental local anesthesia: a report of 2 cases. J Contemp Dent Pract 12:404-407.
- Birn H (1973). Etiology and pathogenesis of fibrinolytic alveolitis (dry socket). Int. J. Oral Surg 2:211-263.
- Bluttner A, Taubenheim L (2009). Aufklärungspflicht des Zahnarztes: Risiken der Leitungsanästhesie. Zahnärztl Mitt 5A:104-106.
- Boronat López A, Peñarrocha Diago M (2006). Failure of locoregional anesthesia in dental practice. Review of the literature. Med Oral Patol Oral Cir Bucal 11:10-13.
- Bourdain, C.L (1925). L'Anesthésie par l'injection intra-ligamentaire pour l'extraction des dents. These de Doctorat, Editions de la Semaine Dentaire, Paris.
- Brännström M, Lindskog S, Nordenvall KJ (1984). Enamel hypoplasia in permanent teeth induced by periodontal ligament anesthesia of primary teeth. J Am Dent Assoc 109:735-736.
- Brännström M, Nordenvall KJ, Hedström KG (1982). Periodontal tissue changes after intraligamentary anesthesia. ASDC J Dent Child 49:417-423.

- Carter G, Gross AN, Lloyd J, Tocchetti R (2003). Current concepts of the management of dental extractions for patients taking warfarin. *Aust Dent J* 48:89-96.
- Castagnola L, Chenaux G, Colombo A (1982). Intraligamentary anesthesia with the peripress syringe. *Quintessenz Int* 13:927-930.
- Chevalier V, Arbab-Chirani R, Tea SH, Roux M (2010). Facial palsy after inferior alveolar nerve block: case report and review of the literature. *Int J Oral Maxillofac Surg* 39:1139-1142.
- Chi D, Kanellis M, Himadi E, Asselin ME (2008). Lip biting in a pediatric dental patient after dental local anesthesia: a case report. *J Pediatr Nurs* 23:490-493.
- Choi EH, Seo JY, Jung BY, Park W (2009). Diplopia after inferior alveolar nerve block anesthesia: report of 2 cases and literature review. *Oral Surg Oral Med Oral Pathol Oral Radiol Endod*. 107:21-24.
- Cohen HP, Cha BY, Spangberg LS (1993). Endodontic anesthesia in mandibular molars: A clinical study. *J. Endod* 19:370-373.
- Csides M (2009). Die intraligamentäre Anästhesie als primäre Methode der zahnärztlichen Lokalanästhesie unter besonderer Betrachtung der angewandten Injektionssysteme und der damit generierten Effekte beim Patienten Diss med. univ. Jena.
- Daubländer M, Kämmerer PW (2014). Lokalanästhesie in der Zahnmedizin. Berlin: Forum-med-dent Aventis.
- Davidson L, Craig S (1987). The use of periodontal ligament injection in children. *J. Dent* 15:204-208.
- DeSantis JL, Liebow C (1996). Four common mandibular nerve anomalies that lead to local anesthesia failures. *J Am Dent Assoc* 127:1081-1086.
- Dirnbacher T (2002). Intraligamentäre Anästhesie vs. Leitungs- und Infiltrationsanästhesie in der Praxis, Diss.med. univ. jena.
- Dirnbacher T (2003). Reduzierung unerwünschter Effekte bei der zahnärztlichen Lokalanästhesie, Diss. med. univ.Jena.
- Dirnbacher T, Glockmann E, Taubenheim L (2003). Die intraligamentäre Anästhesie. Welche Anästhesie ist die richtige?. *Zahnärztl Mitt* 23:44-51.
- Dreyer WP, van Heerden JD, de V. Joubert JJ (1983). The route of periodontal ligament injection of local anesthetic solution. *J Endod* 9:471-474.
- Dumbrigue HB, Lim MV, Rudman RA, Serrano A (1997). A comparative study of anesthetic techniques for mandibular dental extraction. *Am J Dent* 10:275-278.

- Edwards RW, Head TW (1989). A clinical trial of intraligamentary anesthesia. *J Dent Res* 68:1210-1213.
- Einwag J (1982). Die intraligamentäre Anästhesie im Kindes- und Jugendalter. *Dtsch Zahnärztl Z* 37:874-876.
- Endo T, Gabka J, Taubenheim L (2008). Intraligamentary anesthesia: benefits and limitations. *Quintessence Int* 39: 15-25.
- Erlemeier EM (1991). Aktuelle Aspekte der intraligamentären Anästhesie. *Die Quintessenz* 42:471-481.
- Ethunandan M, Tran A.L, Anand R, Bowden J, Seal M.T, Brennan P.A (2007). Needle breakage following inferior alveolar nerve block: Implications and management. *BDJ* 202:395-397.
- Evers H, Haegerstam G (2000). Zahnärztliche Lokalanästhesie. Deutscher Ärzte-Verlag, Köln.
- Faulkner RK (1983). The high-pressure periodontal ligament injection. *Br Dent J* 154:103-105.
- Foster W, Drum M, Reader A, Beck M (2007). Anesthetic efficacy of buccal and lingual infiltrations of lidocaine following an inferior alveolar nerve block in mandibular posterior teeth. *Anesth Prog* 54:163-169.
- Fuhs QM, Walker WA, Gough RW, Schindler WG, Hartman KS (1983). The periodontal ligament injection: Histological effects on the periodontium in dogs. *J Endod* 9:411-415.
- Gaffen AS, Hass DA (2009). Retrospective review of voluntary reports of nonsurgical paresthesia in dentistry. *J Can Dent Assoc* 75:579-579f.
- Galili D, Kaufman E, Garfunkel AA, Michaeli Y (1984). Intraligamentary anesthesia-- a histological study. *Int J Oral Surg* 13: 511-516.
- Garfunkel AA, Kaufman E, Galili D (1985). Intraligamentary anesthesia (transligamentary anesthesia) for health compromised patients. *Gerodontology* 1:63-64.
- Garfunkel AA, Kaufman E, Marmary Y, Galili D (1983). Intraligamentary-intraosseous anesthesia. A radiographic demonstration. *Int J Oral Surg* 12:334-339.
- Giovannitti JA, Nique TA (1983). Status report: the periodontal ligament injection. *J Am Dent Assoc* 106:222-224.
- Glockmann E, Glockmann I, Kulick R (1997). Intraligamentäre Anästhesie. Aspekte der regionalen Schmerzausschaltung in der Zahnheilkunde. *Aktuelles Wissen Hoechst*. 55-64.



Glockmann E, Taubenheim L (2010). Minimalinvasive Schmerzausschaltung - Intraligamentäre Anästhesie. Zahnärztlicher Fach-Verlag, Herne.

Glockmann E, Weber M, Taubenheim L (2007). Schmerzausschaltung vor Vitalextraktionen. Endodontie (16) 3:197-204.

Gray RJM, Lomax AM, Rood JP (1987). Periodontal ligament injection: with or without a vasoconstrictor? Br Dent J 162:263-265.

Grund P, Raab WM, Martin S (1992). Die Infiltrationsanästhesie – Veränderungen von Pulpadurchblutung und Schmerzschwelle. Dtsch Zahnärztl Z 47: 262-265.

Harn SD, Durham TM (1990). Incidence of lingual nerve trauma and postinjection complications in conventional mandibular block anesthesia. J Am Dent Assoc 121:519-523.

Heizmann R (1987). Die intraligamentale zahnärztliche Lokalanästhesie im Vergleich zu den üblichen Anästhesieformen bei der Zahnextraktion. Diss.med., Freie Universität, Berlin.

Heizmann R, Gabka J (1994). Nutzen und Grenzen der intraligamentären Anästhesie. Zahnärztl Mitt 84: 46-50.

Hillerup S, Jensen R (2006). Nerve injury caused by mandibular block analgesia. Int J Oral Maxillofac Surg 35:437-443.

Hochman MN (2007). Eine neue Technologie zur Einzelzahnanästhesie und Weiterentwicklung der intraligamentären Anästhesie. Quintessenz (58) 3: 301-307.

Hochman MN, Friedman MJ, Williams W, Hochman CB (2006). Interstitieller Gewebedruck bei dentalen Injektionen- Eine klinische Studie. Quintessenz (57) 9: 931-938.

Huber HP, Wilhelm-Höft C (1988). Auswirkungen der intraligamentären Anästhesie auf die Zahnbeweglichkeit. Dtsch Zahnärztl Z 43: 313-316.

Kaltenbach M, Glockmann E, Taubenheim L (2006). Zahnarzthaftung: Thematisierung der Risiken und Alternativen der Leitungsanästhesie. Zahnärzteblatt RLP 9:68-70.

Kämmerer PW, Palarie V, Schiegnitz E, Ziebart T, Al-Nawas B, Daubländer M (2012). Clinical and histological comparison of pulp anaesthesia and local diffusion after periodontal ligament injection and intrapapillary infiltration Anaesthesia. J Pain Relief 1:1-5.

Kämmerer PW, Schiegnitz E, von Haussen T, Shabazfar N, Kämmerer P, Willershausen B, Al-Nawas B, Daubländer M (2015). Clinical efficacy of a computerised device (STA™) and a pressure syringe (VarioJect INTRA™) for intraligamentary anaesthesia. Eur J Dent Educ 19:16-22.

- Kämmerer PW, Shabazfar N, Al-Nawas B (2010). Zahnextraktionen unter intraligamentärer Anästhesie: Limitationen und Nebenwirkungen gängiger Methoden der zahnärztlichen Lokalanästhesie. *Dent Implantol* 14:306-313.
- Kaufman E, Galili D, Garfunkel AA (1983). Intraligamentary anesthesia: A clinical study. *J Prosthet Dent* 49:337-339.
- Kaufman E, Epstein JB, Naveh E, Gorsky M, Gross A, Cohen G (2005). A survey of pain, pressure, and discomfort induced by commonly used oral local anesthesia injections. *Anesth Prog* 52:122-127.
- Kaufman E, Weinstein P, Milogram P (1984). Difficulties in achieving local anesthesia. *J Am Dent Assoc* 108:205-208.
- Khoury JN, Mihailidis S, Ghabriel M, Townsend G (2011). Applied anatomy of the pterygomandibular space: improving the success of inferior alveolar nerve blocks. *Aust Dent J* 56:112-121.
- Kohler BR, Casellon L, Laissle G (2008). Gow-Gate technique: A pilot study for extraction procedures with clinical evaluation and review. *Anesth Prog* 55:2-8.
- Krüger E (1993). Operationslehre für Zahnärzte. 8. A., Quintessenz-Verlag Berlin.
- Langbein A (2011). Patientenschonende Lokalanästhesie bei zahnärztlichen therapeutischen Maßnahmen unter besonderer Betrachtung der intraligamentären Anästhesie als primäre Methode der Schmerzausschaltung. Diss. Me., Ludwig-Maximilians-Universität, München.
- Langlais RP, Broadus R, Glass BJ (1985). Bifid mandibular canals in panoramic radiographs. *J Am Dent Assoc* 110:923-926.
- Leilich G, Arndt R, Frenkel G (1985). In-vivo-Messungen zur Ermittlung der bei der intraligamentären Injektion angewandten Kräfte. *Zahnärztl Welt* (94)1:51-53.
- Lin L, Lapeyrolerie M, Skribner J, Shovlin F (1985). Periodontal ligament injection: effects on pulp tissue. *J Endod* 11:529-534.
- Lipp MDW (1992). Die Lokalanästhesie in der Zahn-, Mund- und Kieferheilkunde. Quintessenz-Verlag, Berlin.
- Lipp MDW, Daubländer M (1998). Exogene und endogene Adrenalin-Plasma-Spiegel während zahnärztlicher Behandlung unter Lokalanästhesie. Symposium 20 Jahre Ultracain, in: *Aktuelles Wissen Hoechst* 167-177.
- Littner MM, Tamse A, Kaffe I (1983). A new technique of selective anesthesia for diagnosing acute pulpitis in the mandible. *J Endod* 9:116-119.
- Madan GA, Madan SG, Madan AD (2002). Failure of inferior alveolar nerve block: exploring the alternatives. *J Am Dent Assoc* 133:843-836.

- Malamed SF (1982). The periodontal ligament (PDL) injection: An alternative to inferior alveolar nerve block. *Oral Surg Oral Med Oral Pathol* 53:117-121.
- Malamed SF (1997). *Hand book of local anesthesia*. 4th ed., St. Louis: Mosby-year book. 193- 212.
- Mannucci PM, Aberg M, Nilsson IM, Robertson B (1985). Mechanism of plasminogen activator and factor VIII increase after vasoactive drugs. *Br. J. Haematol* 30: 81-93.
- Mayer R (1976). Die Angst vor der Spritze. *Zahnärztl Welt* 85:1000-1006
- Meyer RA (1971). Effect of anaesthesia on the incidence of alveolar osteitis. *J. Oral Surg* 29: 724-726.
- Meechan JG, Venchard GR, Rogers SN, Hobson RS, Prior I, Tavares C, Melnicenko S (1987). Local anesthesia and dry socket. A clinical investigation of single extractions in male patients. *Int J Oral Maxillofac Surg* 16:279-284.
- Müller W, Henne J (1991). Experimentelle Untersuchungen zur Effektivität der intraligamentären Anästhesie. *Dtsch Zahnärztl Z* 46:815-816.
- Nicholson ML (1985). A study of the position of the mandibular foramen in the adult human mandible. *Anat Rec* 212:110-112.
- Nitzan DW (1983). On the genesis of dry socket. *J. Oral Maxillofac. Surg* 41: 706-710.
- Persson G, Keskitalo E, Evers H (1974). Clinical experiences in oral surgery using a new self-aspirating injection system. *Int J Oral Surg* 3:428-434.
- Pertot WJ, Déjou J (1992). Bone and root resorption. Effects of the force developed during periodontal ligament injections in dogs. *Oral Surg Oral Med Oral Pathol* 74:357- 365.
- Phillips WH (1943). Anatomic considerations in local anesthesia. *J Oral Surg.* 1: 112-121.
- Plagmann H-Chr (1987). Möglichkeiten und Grenzen der intraligamentären Anästhesie (ILA). *Quintessenz* 38:1711-1721.
- Plagmann H-Chr, Jagenow U (1984). Tierexperimentelle Studie zur Reaktion der desmodontalen Gewebe auf intraligamentäre Injektion. *Dtsch Zahnärztl Z* 39:677-682.
- Pogrel MA (2007). Permanent nerve damage from inferior alveolar nerve block-an update to include articaine. *J Calif Dent Assoc* 35:271-273.

Pogrel MA (2009). Broken local anesthetic needles: a case series of 16 patients, with recommendations. J Am Dent Assoc 140: 1517-1522.

Pogrel MA, Thamby S (2000). Permanent nerve involvement resulting from inferior alveolar nerve blocks. J Am Dent Assoc 131:901-907.

Prama R, Padhye L, Pawar H, Rajput N (2013). Efficacy of intraligamentary injections as a primary anesthetic technique for mandibular molars & A comparison with inferior alveolar nerve block. Indian J. of Multidisc. Dent. 3:785-791.

Prothmann M, Claußnetzer N, Taubenheim L, Rossaint R (2009). Systematische Behandlung von Parodontopathien unter intraligamentärer Anästhesie. Parodontologie (20)2:139-148.

Prothmann M, Taubenheim L, Rossaint R (2010). Alternativen zu leitungs- und Infiltrationsanästhesie. Zahnärztl. Welt (119) 9:398-405.

Rahn R (2003). Zahnärztliche Lokalanästhesie. Forum-med-dent Aventis. Frankfurt am Main.

Rahn R, Frenkel G, Atamni F, Shah PM, Schäfer V (1986). Bakteriämie bei intraligamentärer Anästhesie. Zahnärztl Mitt (75)18: 2121-2129.

Rahn R, Shah PM, Haindl U, Frenkel G (1987). Intraligamentäre Anästhesie mit druckbegrenzender Spritze. Die Quintessenz 8: 1329-1336.

Reed KL, Malamed SF, Fonner AM (2012). Local anesthesia part 2: Technical consideration. Anesth Prog 59:127-136.

Roahen JO, Marshall FJ (1990). The effects of periodontal ligament injection on pulpal and periodontal tissues. J Endod 16: 28-33.

Rood JP (1972). Inferior dental nerve block. Routine aspiration and a modified technique. Br Dent J 132:103-105.

Rood JP (1988). Inadequate Analgesia. Dent Update 15: Supplement I, 8-11.

Sawyer DR, Kiely ML (1991). Retromolar foramen: a mandibular variant important to dentistry. Ann Dent 50:16-18.

Saxena P, Gupta SK, Newaskar V, Chandra A (2013). Advances in dental local anesthesia techniques and devices: An update. Natl J Maxillofac Surg 4:19-24.

Shabazfar N, Daubländer M, Al-Nawas B, Kämmerer P.W (2014). Periodontal intraligament injection as alternative to inferior alveolar nerve block – meta-analysis of the literature from 1979 to 2012. Clin Oral Invest 18:351-358.

Shepherd PA, Eleazer PD, Clark SJ, Scheetz JP (2001). Measurement of intraosseous pressures generated by the Wand, high-pressure periodontal ligament syringe, and the Stabident system. J Endod 27: 381-384.

Simon DE, Jacobs TL, Senia ES, Walker WA (1982). Intraligamentary anesthesia: Aid in endodontic diagnosis. *Oral Surg Oral Med Oral Pathol* 54:77-78.

Smith MH, Lung KE (2006). Nerve injuries after dental injection: A review of the literature. *J Can Dent Assoc* 72:559-564.

Smith GN, Pashley DH (1983). Periodontal ligament injection: Evaluation of systemic effects. *Oral Surg Oral Med Oral Pathol* 56:571-574

Smith GN, Walton RE (1983). Periodontal ligament injection: distribution of injected solutions. *Oral Surg Oral Med Oral Pathol* 55:232-238.

Stoll P, Bührmann K (1983). Die intraligamentäre Anästhesie bei der Zahnextraktion von Patienten mit hämorrhagischer Diathese. *Zahnärztl Welt* 92:54-55.

Stoll P, Krekeler G, Bührmann K (1986). Lokale Schmerzausschaltung bei hämorrhagischer Diathese. *Dtsch Zahnärztl Z* 41:405.

Tagger M, Tagger E, Sarnat H (1994). Periodontal ligament injection - spread of the solution in the dog. *J Endod* 20:283-287.

Tagger E, Tagger M, Sarnat H, Mass E (1994). Periodontal ligament injection in the dog primary dentition: spread of local anaesthetic solution. *Int J Paediatr Dent* 4:159-166.

Taghavi Zenouz A, Ebrahimi H, Mahdipour M, Pourshahidi S, Amini P, Vatankhan M (2008). The incidence of intravascular needle entrance during inferior alveolar nerve block injection. *J Dent Res Dent Clin Dent Prospects* 2:38-41.

Thomason WM, Dixon GS, Kruger E (1999). The west coast study. II: dental anxiety and satisfaction with dental services. *N Z Dent J* 95:44-48.

Tobien V, Schulz D (2000). Veränderte intradesmodontale Injektion. *ZMK*. (16) 5: 332-333.

Torabinejad M, Peters DL, Peckham N, Rentschler LR, Richardson J (1993). Electron microscopic changes in human pulps after intraligamentary injection. *Oral Surg Oral Med Oral Pathol* 76: 219-224.

Tsirlis AT, Iakovidis DP, Parissis NA (1992). Dry socket: frequency of occurrence after intraligamentary anesthesia. *Quintessence Int* 23:575-577.

Tzermpos FH, Cocos A, Kleftogiannis M, Zarakas M, Iatrout I (2012). Transient delayed facial nerve palsy after inferior alveolar nerve block anesthesia. *Anesth Prog* 59:22-27.

Van Wijk AJ, Hoogstraten J (2009). Anxiety and pain during dental injections. *J Dent* 37: 700-704.

Vasconcelos BC, Freitas KC, Canuto MR (2008). Frequency of positive aspirations in anesthesia of the inferior alveolar nerve by the direct technique. *Med Oral Patol Oral Cir Bucal* 13:371-374.

Von Haussen T (2011). Evaluation einer Kohortenstudie in Hinsicht auf die klinische Praktikabilität zweier unterschiedlicher intraligamentärer Spritzensysteme. Diss. med., Universität. Mainz.

Walton RE, Abbott BJ (1981). Periodontal ligament injection: a clinical evaluation. *J Am Dent Assoc* 103: 571-575.

Walton RE, Garnick JJ (1982). The periodontal ligament injection: histologic effects on the periodontium in monkeys. *J Endod* 8:22-26.

Weber E (1981). Arzneimittelkomplikationen durch Unverträglichkeit und Allergie. *Zahnärztl Mitt* 71:1004-1010

Weber M (2005). Reduzierung der unerwünschten Nebeneffekte bei der zahnärztlichen Lokalanästhesie unter besonderer Berücksichtigung der Erfordernisse für endodontische Maßnahmen. Diss. med., Universität, Jena.

Weber M, Taubenheim L, Glockmann E (2006). Schmerzausschaltung vor indizierten endodontischen Behandlungen. *ZWR Dtsch Zahnärzteblatt*. 115(10): 421-433.

Wright EF (2011). Medial pterygoid trismus (myospasm) following inferior alveolar nerve block: case report and literature review. *Gen Dent* 59:64-67.

Zugal W (2001). Die intraligamentäre Anästhesie in der zahnärztlichen Praxis. *Zahnärztl Mitt* (91) 6:46-52.

Zugal W, Taubenheim L (2008). Komplikationen und Grenzen der intraligamentären Anästhesie. *Stomatologie* (105) 8:187-195.

Zugal W, Taubenheim L, Schulz D (2005). Triade des Anästhesie - Erfolgs: Instrumente – Anästhetika – Methoden-Beherrschung. *Z Stomatol* 102(1):9-14.

### **10. Declaration of original work**

I hereby declare that the work presented here is, to the best of my knowledge and belief original and the results of my own investigations, except as acknowledged, and has not been submitted, either in part or whole, for a degree at this or any other University. Formulations and ideas taken from other sources are cited as such. This work has not been published yet.

Rostock, den 22.07.2016

Ahmed Adubae

## **11. Theses**

From the results of this present study, the following theses are derived:

- 1) Intraligamentary anesthesia is significantly less painful to the patient than the conventional inferior alveolar nerve block.
- 2) Intraligamentary anesthesia has significantly shorter latency time compared to the inferior alveolar nerve block.
- 3) Intraligamentary anesthesia enables a shorter duration of treatment.
- 4) Intraligamentary anesthesia has a shorter duration of soft tissue anesthesia that is usually enough to complete the majority of dental treatment measures.
- 5) The profoundness of intraligamentary anesthesia is comparable to that of conventional inferior alveolar nerve block.
- 6) The success rate of intraligamentary anesthesia in extraction of mandibular posterior teeth is comparable to that of inferior alveolar nerve block.
- 7) The periodontal ligament injection of local anesthetic solution is not associated with a significant increase in the frequency of occurrence of dry socket.



## 12. Curriculum Vitae

Ahmed Adubae

Dethardingstraße 86 – 18057 Rostock

[ahmed.adubae@med.uni-rostock.de](mailto:ahmed.adubae@med.uni-rostock.de)

### - Personal data:

---

Name: Adubae, Ahmed  
Date of birth: 09.03.1978  
Place of birth: Taiz – Yemen  
Marital status: Married, three children.  
Nationality: Previously Yemeny, actually German  
Occupation: Oral surgeon

### - Education and study

---

#### Post-Graduate

2009-2012 Master Degree in Oral Surgery (Fachzahnarzt)  
Zahnärztekammer Mecklenburg-Vorpommern.

#### Under-Graduate

1998-2003 Bachelor Degree in dentistry,  
Faculty of Medicine and Health Sciences, Aden University,  
Yemen.

#### Primary and Secondary School

1994-1997 Secondary education, Lutfi Aman Secondary School, Aden.  
1985-1994 Primary education, Al-Ghazaly School, Taiz.

## **- Professional Experience**

---

- 2012-2016 Oral surgeon – Department of Oral and Plastic Maxillofacial Surgery, University of Rostock, Germany
- 2009-2012 Postgraduate student, Department of Oral and Plastic Maxillofacial Surgery, University of Rostock.
- 2008-2009 One year course for German language at University of Rostock.
- 2004-2008 Instructor and Dentist – Department of Oro-maxillofacial Surgery, Faculty of Dentistry, University of Aden, Yemen.
- 2003-2004 Dentist – Department of Oro-maxillofacial Surgery, Al-Gamhoria Teaching Hospital, Aden, Yemen.

## **- Articles and Publications**

---

- Adubae A, Buttchereit I, Kämmerer W-P (2016). Extraktion unter ILA bei einer Phobie-Patientin. ZAHNÄRZTLICHE MITTEILUNGEN 106(5):42-45.

### **13. Acknowledgements**

This thesis would not have been possible without the guidance and the help of several individuals who in one way or another contributed and extended their valuable assistance and available support in the preparation and completion of this study. I would like to owe my deepest gratitude to:

Priv. Doz. Dr. med. habil. Dr. med. dent. Peer Wolfgang Kämmerer, supervisor of this thesis, for the opportunity of doing this research and for all the support given during the development of this work.

Prof. Dr. med. Dr. med. dent. Bernhard Frerich, Director of the Department of Oral and Plastic Maxillofacial Surgery, for all the effort and support during my time at his Department and the development of this work.

Dr.med. dent. Ingo, Buttchereit, special thanks for the encouragement, for all the fun moments spent together and for the help in tacking of photos.

All the colleagues in the Department of Oral and Plastic Maxillofacial Surgery, for receiving me so well and providing me a friendly work environment.

My family, for everything they taught me and for being present at all time.

My wife Nagwa for the love, friendship, affection and patience. None of this would have been possible without you.

## 14. Appendix

### 13.1. Data collection sheet

**Studie:** Vergleichende Evaluation der intraligamentären Anästhesie und der Leitungsanästhesie des Nervus alveolaris inferior zur Zahnextraktion im Unterkieferseitenzahnbereich

#### 1. Persönliche Daten und Anamnese

Patientenname:..... Patientennummer:.....

Geburtsdatum:..... ☐ männlich ☐ weiblich

Größe:                    |\_\_|\_\_|\_\_| cm                    Gewicht:                    |\_\_|\_\_|\_\_|, |\_\_| kg

Telefonnummer:.....

Datum der Behandlung: |\_\_|\_\_| |\_\_|\_\_| |\_\_|\_\_|    Behandler:.....

Schmerzen vor Behandlungsbeginn?                    ☐ ja                    ☐ nein

Schmerzmittel vor Behandlungsbeginn?                    ☐ ja                    ☐ nein

Wenn ja, welche Schmerzmittel?

Letzte Einnahme vom Schmerzmittel vor der Behandlung?                    |\_\_|\_\_| |\_\_|\_\_| |\_\_|\_\_|

Begleiterkrankungen?.....

.....

Begleitmedikation:.....

.....

Sind allergische Reaktionen auf Lokalanästhetika bekannt?

Wenn ja, welche?

Sind allergische Reaktionen auf Stabilisatoren, z.B. Sulfit bekannt?

Wenn ja, welche?

#### 2. Behandlung (Behandler)

Zielzahn bzw. Regio, die für geplanten Eingriff zu anästhesieren ist                    |\_\_|\_\_|

Anästhesie vor dem Eingriff:                    ☐ IANB                    ☐ ILA

Menge LA                    |\_\_|, |\_\_|\_\_| ml                    Menge Vasokonstriktor                    |\_\_|, |\_\_|\_\_| ml

Uhrzeit bei Injektion                    |\_\_|\_\_|:|\_\_|\_\_|

Positive Aspiration?                    ☐ ja                    ☐ nein

Traten immediate Komplikationen auf?                    ☐ ja                    ☐ nein

Wenn ja, welche? .....

Wirkungseintritt von Anästhesie Uhrzeit                    |\_\_|\_\_|:|\_\_|\_\_|



### Traten Beschwerden auf?

Ist Wundheilungsstörung vorhanden? ☐ Ja ☐ Nein

Ist Wundheilungsstörung vorhanden? ☐ Ja ☐ Nein